

Electrophysiological Study in Patients with Cervical Radiculopathy

Hussein G. Kaddoori *PhD*

Dept. of Physiology, College of Medicine, Al-Nahrain University, Baghdad, Iraq

Abstract

Background	Cervical radiculopathy is defined as a pathological process affecting the cervical nerve root(s). Electromyography (EMG), nerve conduction studies (NCS), and somatosensory evoked potentials (SEPs) are frequently used to evaluate spinal cord and nerve root function.
Objective	To evaluate the sensitivity of different SEP components in detecting cervical nerve root lesions, as well as to test the NCS, and EMG, in patients with cervical radiculopathy.
Methods	In this case control study, 41 patients with cervical radiculopathy and 40 healthy volunteers took part. Sensory and motor NCS of the ulnar and median nerves, EMG of the deltoid, biceps brachii, and abductor brevis, and SSEP of the median nerve were performed on each participant.
Results	There was no difference in the motor and sensory NCS data between the study groups. The EMG of the muscles under investigation differed significantly between the two groups in terms of both duration and amplitude, with the exception of the abductor brevis muscle, which did not exhibit any differences. SEP data indicates that the patient's N9, N13, P14, and N20 latencies were all increased, as well as the patient's N13-N9, N20-N13, and N20-N9 interpeak latencies. The N13 and P14 latencies exhibited the highest sensitivity and specificity.
Conclusion	SEPs are more sensitive in identifying mild posterior column dysfunction in patients with cervical radiculopathy, which is at least imperceptible on routine NCS. SEP testing is an essential adjunctive diagnostic method for evaluating the spinal cord and nerve roots electrophysiologically. The N13 and P14 components have the highest sensitivity and specificity when comparing the patient and control groups.
Keywords	Cervical radiculopathy, NCS, EMG, SEP
Citation	Kaddoori HG. Electrophysiological study in patients with cervical radiculopathy. <i>Iraqi JMS</i> . 2024; 22(1): 20-30. doi: 10.22578/IJMS.22.1.3

List of abbreviations: AUC = Area under the curve, CSCT = Central sensory conduction time, EMG = Electromyography, NCS = Nerve conduction study, ROC = Receiver operating curve, SEP = Somatosensory evoked potential

Introduction

One or more cervical nerve roots may be affected by a pathological disorder called cervical radiculopathy, which can be categorized as having an acute and degenerative compressive etiology or a nondegenerative one ⁽¹⁾.

The functional status of the central nervous system is assessed using neurophysiological methods in addition to the clinical examination. To assess spinal cord and nerve root function, somatosensory evoked potentials (SEPs), nerve conduction studies (NCS), and electromyography (EMG) are widely used. The advantages of electrophysiological testing are numerous; patients who exhibit weakness as a result of pain, those with atypical symptoms, and those whose imaging results do not show a focalizing lesion can all

benefit from them. They facilitate quantitative longitudinal assessment and aid in diagnosis as well. Additionally, they aid in ruling out additional neuromuscular conditions that mimic cervical radiculopathy, such as motor neuron disease and peripheral neuropathy⁽²⁻⁴⁾. The C4-C8 and T1 roots are the only ones represented in the upper extremity that can be evaluated by electrodiagnostic studies for cervical radiculopathy⁽⁵⁾. The difficulties in identifying nerve root involvement caused by cervical nerve root lesions are well known to clinical neurologists. Numerous electrophysiological methods have been employed in those circumstances to evaluate nerve root functions⁽⁶⁾.

The NCS includes the compound muscle action potential and sensory nerve action potential, which are used to assess the function of motor and sensory nerves, respectively⁽⁷⁾. The F wave and H-reflex are late responses examining the nerve root conduction⁽⁸⁾. F waves, however, may be abnormal in severe nerve root, plexus, or peripheral nerve lesions but are frequently normal in less severe lesions⁽⁹⁾.

Patients with chronic cervical radiculopathy may have changes in their needle EMG that are indicative of chronic neurogenic injury. However, it is not advised to diagnose radiculopathy solely based on the morphology of motor unit action potentials⁽⁹⁾. This is because it is extremely uncommon for the motor axons innervating a given muscle to be injured in a number sufficient to produce obvious changes in the recruitment pattern⁽⁹⁾. Additionally, the evaluation of motor unit duration, amplitude, and polyphasia required to characterize chronic radiculopathy accurately is limited by the time constraints and sampling size imposed by a proper motor unit analysis⁽⁹⁾.

Evoked potentials (EPs) offer non-invasive ways to measure the nervous system's neural activity. The sensory and motor pathways' unique anatomical features and their proximity to regions associated with vegetative, conscious, and cognitive processes make EPs a

valuable tool for identifying and locating neurological disorders. When compared to conventional methods, they can detect disorders of the nervous system⁽¹⁰⁾.

The SEPs are large-fiber somatosensory pathway-recorded time-locked electric potentials stimulated at the sensory peripheral nerves. The dorsal column's transduction capabilities are primarily reflected by the SEPs⁽¹¹⁾. They can assess afferent nerve fiber dysfunction in radiculopathies, which is a theoretical advantage. Dermatome SEPs, in particular, ought to be helpful as they evaluate the sensory fibers of a single nerve root⁽²⁾.

As much debate has surrounded the use of SEPs in the evaluation of radiculopathies. The ability of SEPs to detect injury to afferent fibers, which is a common cause of symptoms and signs in radiculopathies, has generated interest in using them to evaluate radiculopathies^(9,12).

This study objectives were to examine the NCS, EMG, and SEPs in patients with cervical radiculopathy and to assess the sensitivity of various SEP components in detecting cervical nerve root lesions.

Methods

The Neurophysiology Unit at Al-Imamein Al-Kadhimein Medical City hosted this study from February 2022 to March 2023. The Institute Review Board of the College of Medicine at Al-Nahrain University gave its approval to the study. Each participant who wanted to take part in the study had to give an informed consent for participation.

Subjects

A senior neurosurgeon and/or orthopedic surgeon diagnosed a total of 40 patients (24 men and 16 women; mean age 47.92±11.99 years) with cervical radiculopathy who had no history of diabetes mellitus, alcoholism, uremia, or other metabolic diseases that might have affected the electrophysiological test. The illness lasted from one to four years.

Another 41 healthy volunteers (aged 48.27 ± 12.01 years; 22 men, 19 women) without neurological disorders consented to take part in the study. Their physical exams were unremarkable, and they did not take any medications that might have impacted the electrophysiological evaluation. When available, participants underwent routine X-rays and magnetic resonance imaging of the cervical region.

Neurophysiologic studies

Electrophysiological examination was conducted by a neurophysiologist. During the test procedures, the examination room's temperature was kept between 25 and 28°C, and a thermometer was used to measure the skin's temperature at the axilla, which was measured to be between 36 and 37°C.

Sensory and motor nerve conduction studies

Median and ulnar distal sensory latency, sensory nerve action potential amplitude, and conduction velocity were studied by the antidromic method. Also, median and ulnar distal motor latency, distal and proximal compound muscle action potential amplitude, motor nerve conduction velocity, and F wave minimum latency of the same nerves were done. The motor parameters were studied from abductor pollicis brevis and abductor digiti minimi muscles, respectively according to methods adopted by Preston and Shapiro⁽¹³⁾. The electromyographic settings of the sensory study were frequency: 100 Hz-10 KHz, sweep speed: 2 msec/Division and sensitivity: 10 μ V/Division, while for the motor study was frequency: 100-500 Hz, sweep speed: 5 msec/Division and sensitivity: 1 mV/Division.

Needle EMG

The C5, 6, 7, and 8 root-innervated muscles were the focus of a needle EMG study that was carried out by standard procedures⁽¹⁴⁾ using a disposable concentric needle electrode, this is done bilaterally on each subject's abductor pollicis brevis (APB), biceps brachii and deltoid

muscles. The muscles were observed at rest to look for spontaneous activity. Twenty single motor units and a minimum muscle contraction to activate 3-6 motor units from each muscle were assessed for their duration and amplitude. The sweep speed was set at 3-5 msec/cm, and the gain was set at 200 μ V/cm.

Somatosensory evoked potentials

According to the International Federation of Clinical Neurophysiology standards⁽¹⁵⁾, the median SEPs were elicited by electrical stimuli with square waves of 0.2 msec duration at 4 KHz high pass filter and 500 Hz low pass filter, gain 5 μ V/Division, and the time of analysis was set at 50 msec applied to the median nerves of both arms sequentially.

A 10 k Ω . electrode impedance was maintained. Even though it is known that two sets of 500 stimuli are sufficient to reproduce a good graphic response, three sets of 1000 responses each were averaged and superimposed to ensure consistency and facilitate the analysis. 10 mA was the maximum stimulus current. The thenar muscles twitched slightly in response to the stimulus intensity.

A stimulating electrode was located over the median nerve, near the wrist. The recording disposable subdermal monopolar needle recording electrodes (EL T100, Italy), with a length of 13 mm and diameter of 0.45 mm, were positioned at the following sites: Erb's point on each side (Epi and (Epc), over the second and fifth cervical spine processes (C2S, C5S), scalp over the contralateral cortex (Cpc), and cephalic Fz electrode (Reference) (based on the international 10/20 system⁽¹⁶⁾). The Cpc are scalp electrodes located contralateral to the stimulus, halfway between C3 and P3 or C4 and P4, where Cpc is contralateral to the stimulus. These electrodes are over the motor-sensory cortex. Epi is Erb's point ipsilateral to the stimulus; Epc is Erb's point contralateral to the stimulus. The recommended montage is Channel 1: Cpc-Fz, Channel 2: C2s-Fz, Channel 3: C5s-Fz, and Channel 4: Epi-Epc.

The responses of N9 (Erb's point response), N13 (cervical spinal cord response), P14 (cervical-medullary response), and N20 (cortical response), as well as interpeak latencies (central sensory conduction time), were used to evaluate the SEP recordings. The latency of these responses was the variable analyzed. Based on the normal or delayed latency when compared to healthy subjects, the data were analyzed.

Statistical Analysis

Microsoft Office Excel 2010 and the Statistical Package of Social Sciences (SPSS) version 25 software were used to produce the statistical analysis. Every piece of data was expressed as mean \pm standard deviation (SD). To determine differences between groups, data from each patient and control group were compared using an independent sample t-test. To compare the right and left sides within the

same group, a paired t-test was used. P values of 0.05 or lower were regarded as significant. Receiver operating curve (ROC) analysis was used to determine the sensitivity and specificity of the cutoff values for prolonged latencies and central sensory conduction time (CSCT).

Results

The demographic characteristics of the study population are shown in table (1). Regarding age and sex, there were not any significant variations between the patients and controls. The patients' group's disease had been present for 1 to 4 years, 72.5 % of patients had numbness and tingling, 85% had pain, and 25% had weakness in their upper extremities. Examining patients revealed that 7.5% had a diminished C5 reflex, 20% had a diminished C6 reflex, and 30% had a diminished C7 reflex.

Table 1. Demographic characteristics of the study population

Variables		Patients (n=40)	Controls (n=41)	P value
Age (years)	Mean \pm SD	47.92 \pm 11.99	48.27 \pm 12.01	0.695
	Sex			
	Males	26 (54.55%)	22 (40.24%)	0.299
	Females	14 (45.55%)	19 (59.8%)	
Disease duration (year)		1-4		
Signs and symptoms*	Neck pain	34 (85%)		
	Numbness and tingling	29 (72.5%)		
	Weakness	10 (25%)		
	Diminished reflexes, C5	3 (7.5%)		
	Diminished reflexes, C6	8 (20%)		
	Diminished reflexes, C7	12 (30%)		

* The patient may have more than one sign and symptom

No significant difference between the studied groups was shown in any component, according to the NCS data of the median and ulnar nerves (Table 2).

Regarding the EMG results of the examined muscles, table (3) demonstrates that there were no differences between the studied groups in the duration and amplitude of the motor unit action potentials recorded from the

Kaddoori, *Electrophysiological Study in Cervical Radiculopathy*

abductor polices brevis muscles. Contrarily, the patient group's biceps brachii and deltoid muscle duration and amplitude were

significantly longer and higher in comparison to the controls, respectively ($P < 0.001$).

Table 2. Nerve conduction data of patients with cervical radiculopathy versus controls

Parameters	Nerve	Patients' hands N= 80	Controls' hands N = 82	P value
SL (msec)	Median	2.30±0.35	2.35±0.34	0.813
	Ulnar	2.32±0.32	2.23±0.33	0.838
SNAP (µV)	Median	29.95±6.05	30.49±7.16	0.117
	Ulnar	27.52±5.21	27.61±6.26	0.136
SNCV (m/sec)	Median	55.76±5.69	56.38±6.46	0.645
	Ulnar	56.14±5.35	57.69±6.79	0.051
DML (msec)	Median	3.05±0.50	2.85±0.36	0.146
	Ulnar	2.50±0.39	2.58±0.39	0.803
Distal CMAP (mV)	Median	8.08±2.13	7.51±1.92	0.337
	Ulnar	8.73±3.36	8.07±3.26	0.214
Proximal CMAP (mV)	Median	8.45±2.28	7.65±2.19	0.490
	Ulnar	7.77±2.82	7.49±2.54	0.193
MNCV (m/sec)	Median	58.46±5.00	56.78±7.99	0.288
	Ulnar	57.36±9.72	57.43±7.71	0.416
F wave latency (msec)	Median	28.02±4.85	27.52±3.49	0.141
	Ulnar	25.05±1.75	24.57±2.01	0.117

The data presented as mean±SD, SL = Sensory latency, SNAP = Sensory nerve action potential, SNCV = Sensory nerve conduction velocity, DML, Distal motor latency, CMAP = Compound muscle action potential, MNCV = motor nerve conduction velocity

Table 3. Electromyographic features of controls versus patients with cervical radiculopathy

Muscle	Parameter	Patients' hands N= 80	Controls' hands N = 82	P value
ABP	Duration (msec)	9.72±0.66	10.06±0.49	0.139
	Amplitude (µV)	921.23±100.69	935.18±98.11	0.320
BB	Duration (msec)	14.09±2.64	11.63±0.92	<0.001
	Amplitude (µV)	810.75±265.98	322.51±45.06	<0.001
Deltoid	Duration (msec)	14.12±2.92	11.49±1.02	<0.001
	Amplitude (µV)	646.35±286.69	353.32±63.41	<0.001

The data presented as mean±SD, APB = Abductor polices brevis, BB = Biceps brachii

When compared to the controls, the patients' N9 SEP latency was significantly lengthened

($P=0.055$). Similarly, the N13, P14, and N20 latencies were significantly prolonged in the

patients when compared to the controls ($P < 0.001$). Following the values of the controls, the N13-N9, N20-N13, and N20-N9 CSCT were

significantly prolonged in patients ($P < 0.001$) as indicated in table (4).

Table 4. Somatosensory evoked potentials in patients with cervical radiculopathy versus controls

Parameters		Patients' hands N= 80	Controls' hands N = 82	P value
Latency (msec)	N9	9.39±0.29	9.26±0.22	0.055
	N13	14.58±1.70	12.96±0.68	<0.001
	P14	16.81±1.89	14.75±0.76	<0.001
	N20	24.03±4.47	20.73±1.16	<0.001
CSCT (msec)	N13-N9	5.18±1.76	3.7±0.71	<0.001
	N20-N13	9.46±3.56	7.77±1.39	<0.001
	N20-N9	14.60±4.50	11.44±1.20	<0.001

CSCT = Central sensory conduction time

To assess the sensitivity and specificity, the receiver operating characteristic (ROC) curve was used. The area under the curve (AUC) for left N9 was 0.667, 95% confidence interval (CI) = 0.547-0.787, $P = 0.01$. The test's sensitivity and specificity were 63% and 71%, respectively, at a cut-off value of N9 = 9.35 msec. The AUC for left N13 was 0.839, 95% CI = 0.752-0.925, $p < 0.001$. The test's sensitivity and specificity

were 80% and 83%, respectively, at a cut-off value of N13 = 13.25 msec.

The AUC for left P14 was 0.871, 95% CI = 0.787-0.955, $P < 0.001$. The test's sensitivity and specificity were 80% and 81%, respectively, at a cut-off value of P14 = 15.35 msec. The AUC for left N20 was 0.743, 95% CI = 0.631-0.855, $p < 0.001$. The test's sensitivity and specificity were 63% and 81%, respectively, at a cut-off value of N20 = 21.85 msec (Figure 1).

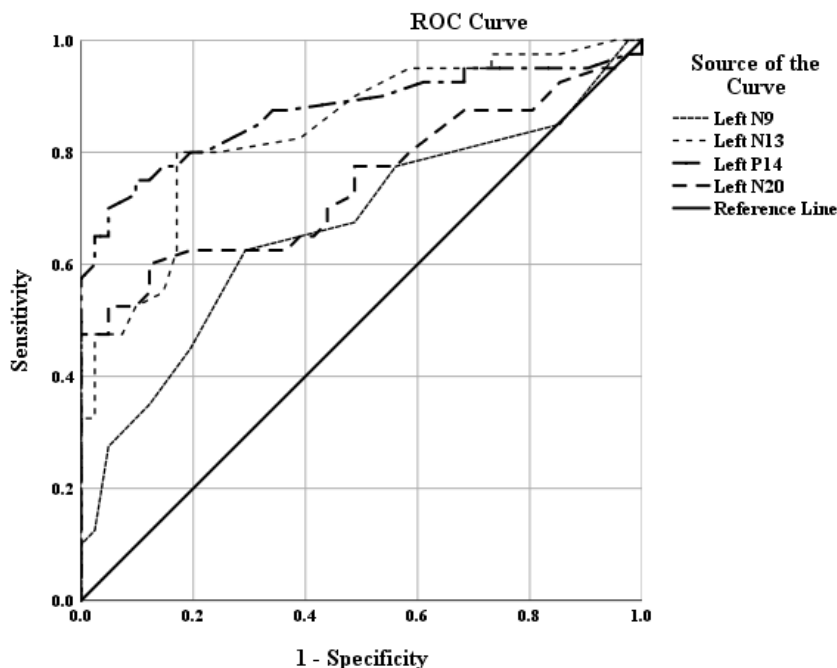


Figure 1. ROC curve of left-sided SEPs in the context of discrimination between patients and controls

The AUC for left CSCT N13-N9 was 0.783, 95% CI = 0.683-0.882, $P < 0.001$. The test's sensitivity and specificity were 78% and 66%, respectively, at a cut-off value of CSCT N13-N9 = 3.85 msec. The AUC for left CSCT N20-N13 was 0.635, 95% CI = 0.512-0.758, $P = 0.036$. The test's sensitivity and specificity were 55% and 61%, respectively, at a cut-off value of CSCT N20-N13 = 8.25 msec. The AUC for left CSCT N20-N9 was 0.734, 95% CI = 0.622-0.846, $P < 0.001$. The test's sensitivity and specificity were 63% and 66%, respectively, at a cut-off value of CSCT N20-N9 = 21.25 msec (Figure 2).

The AUC for right N9 was 0.602, 95% CI = 0.547-0.787, $P = 0.115$. The test's sensitivity and specificity were 68% and 54%, respectively, at a cut-off value of N9 = 9.25 msec. The AUC for right N13 was 0.830, 95% CI = 0.752-0.925, $P < 0.001$. The test's sensitivity and specificity were 75% and 71%, respectively, at a cut-off value of N13 = 13.45 msec.

The AUC for right P14 was 0.890, 95% CI = 0.787-0.955, $P < 0.001$. The test's sensitivity and specificity were 85% and 83%, respectively, at a cut-off value of P14 = 15.35 msec. The AUC for right N20 was 0.748, 95% CI = 0.631-0.855, $P < 0.001$. The test's sensitivity and specificity were 63% and 73%, respectively, at a cut-off value of N20 = 21.65ms (Figure 3).

The AUC for right CSCT N13-N9 was 0.781, 95% CI = 0.678-0.884, $P < 0.001$. The test's sensitivity and specificity were 65% and 78%, respectively, at a cut-off value of CSCT N13-N9 = 4.4 msec. The AUC for right CSCT N20-N13 was 0.593, 95% CI = 0.468-0.718, $P = 0.150$. The test's sensitivity and specificity were 58% and 39%, respectively, at a cut-off value of CSCT N20-N13 = 7.05 msec. The AUC for right CSCT N20-N9 was 0.706, 95% CI = 0.589-0.823, $P = 0.001$. The test's sensitivity and specificity were 63% and 68%, respectively, at a cut-off value of CSCT N20-N9 = 12.0 msec (Figure 4).

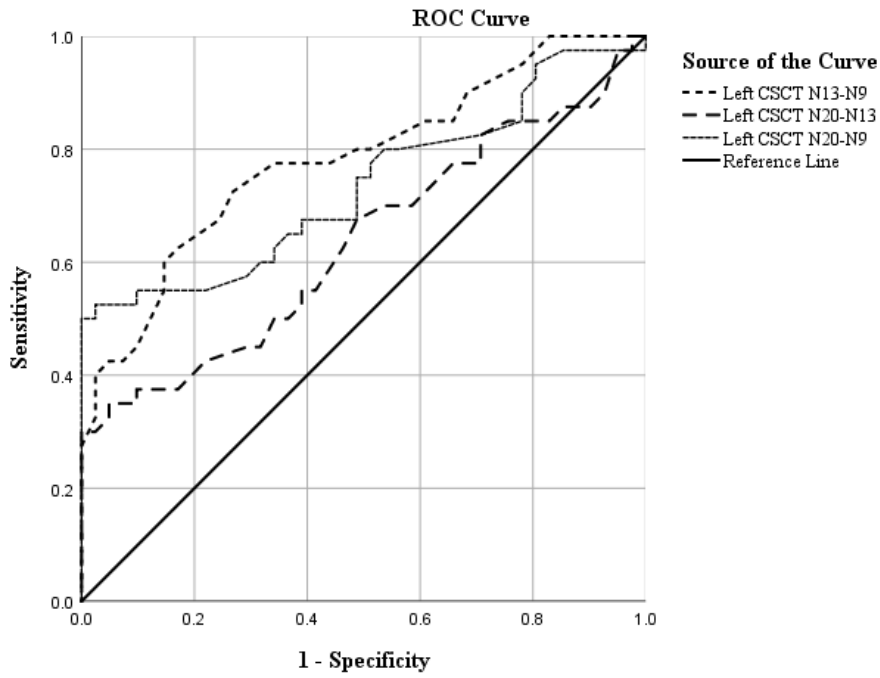


Figure 2. ROC curve of left-sided CSCT of SEP components in the context of discrimination between patients and controls

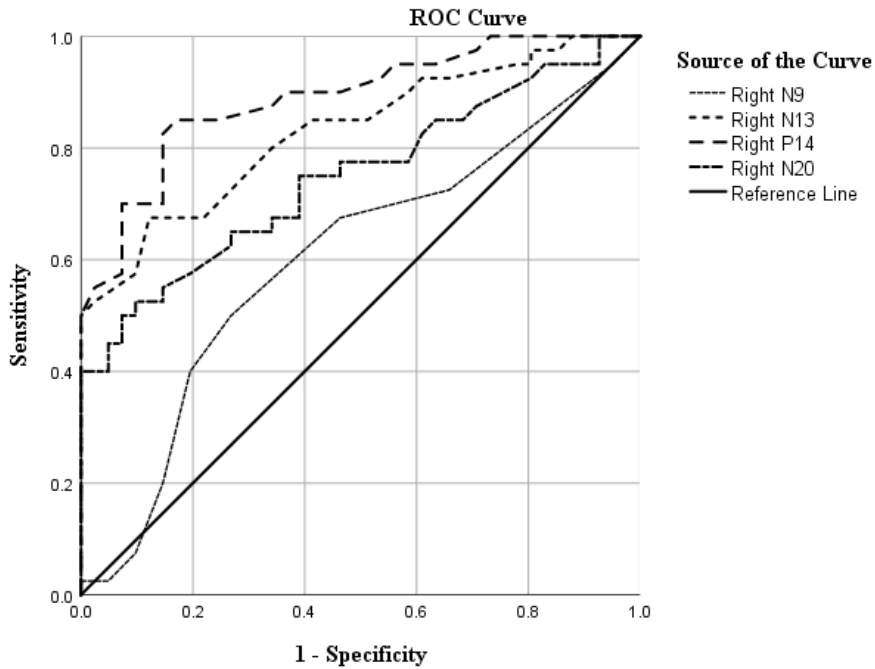


Figure 3. ROC curve of right-sided SEPs in the context of discrimination between patients and controls

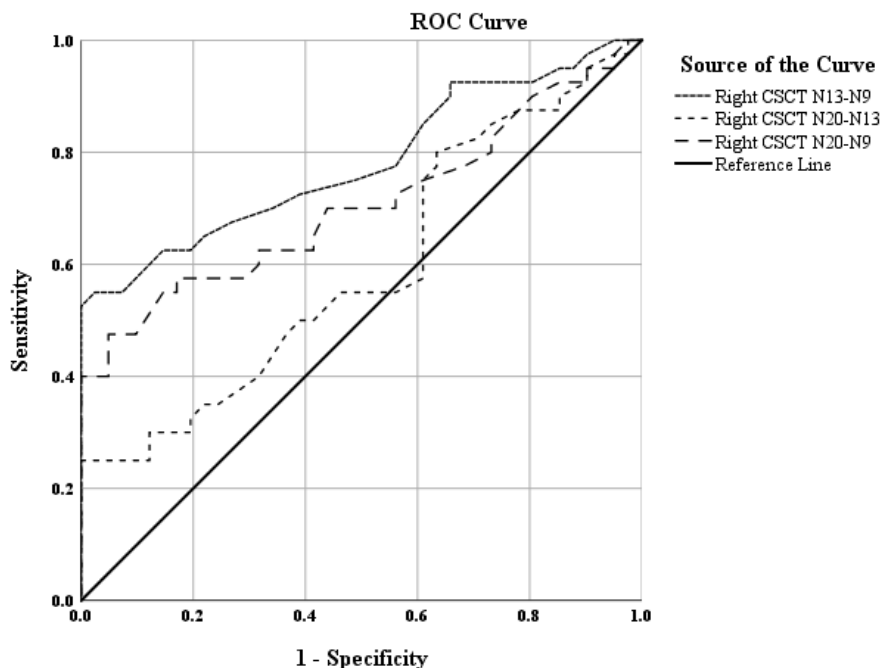


Figure 4. ROC curve of right-sided CSCT of SEP components in the context of discrimination between patients and controls

Discussion

Demographic data

The age of the patients in the study fell within the range reported by numerous studies (17,18), and current study found that males were more affected than females, which was also consistent with the findings of other studies (18). The C7 nerve root is most frequently affected, followed by the C6 nerve root. Other studies (19,20) also reported these values. The most frequent presenting symptom in patients with cervical radiculopathy in this study was radicular pain, followed by paresthesia. A result that is consistent with the findings of other study (21).

Nerve conduction data

In the present study, the sensory NCS of the studied nerves in patients with cervical radiculopathy were not significantly different from those of the control values. Other studies (2,22) have also noted these results. The amplitude and latency of the sensory nerve action potential (SNAP) will typically be normal in radicular processes. This happens as a result of the nerve root being compressed close to

the sensory dorsal root ganglion. If an anomaly is discovered during the examination, the cause could be a completely unrelated diagnosis or a coexisting pathology.

The patients didn't differ significantly from the controls in terms of the sensory and motor NCS. This is a result of the nerve root's nerve fascicles only being partially affected (22). Axon loss occurs, however, if there is enough root compression such that the distal portions of axons are not continuous with the cell body. In comparison to the contralateral limb, the amplitude may be reduced if more than 50% of the motor axons are damaged (22). While NCS may not necessarily indicate cervical radiculopathy, it is crucial to test them to take other differential diagnoses into account.

Needle EMG

In this study, the majority of the proximal muscles' EMGs displayed abnormal spontaneous activity in the form of grade 1-2 fibrillation potentials, which are caused by muscle fibers firing on their own. These results were also observed first at the proximal muscles and then at distal muscles (22).

Additionally, the motor unit action potential (MUAP) amplitude and duration showed neuropathic polyphasic motor units as they were significantly different from those of the control subjects. If reinnervation has taken place in conjunction with the growth of fresh collateral axons, polyphasic motor units may be present ⁽²³⁾. However, the presence of polyphasic potentials alone should not be used to make the diagnosis of cervical radiculopathy. The paraspinal muscles are the ones most frequently affected by reinnervation, which progresses over time to the distal muscles in the extremity ⁽²²⁾.

Somatosensory evoked potentials

In the current study, patients with cervical radiculopathy had significantly different SEPs from the control group (prolonged peripheral N9, spinal N13, cervical-medullary P14, and parietal N20 latencies indicating that the pathway's myelin has been impaired ⁽¹⁰⁾, as well as prolonged N13-N9, N20-N13, and N20-N9 CSCT. These results concurred with those of other researchers ^(24,25). Among the other SEP parameters in present study, N13 and P14 latency prolongation exhibits the highest specificity and sensitivity. These two peaks are indicators of spinal cord activity ⁽²⁶⁾.

Specifically, a far-field P14 component reflects activity in the dorsal column nuclei and/or the caudal medial lemniscus within the lower medulla, and a near-field N13 component is generated by the postsynaptic activity of neurons in the grey matter of the lower cervical spinal cord ⁽²⁷⁾.

Additionally, this study showed a higher N13-N9 interpeak latency, which may point to cervical root or lower cervical cord disease. Other researchers ^(28,29) have also supported this conclusion. N20-N13 interpeak latency was also seen to be prolonged in patients with cervical radiculopathy. Given the strong evidence that the N13 component is primarily a postsynaptic generated in the posterior horns at the level of C4-C7, this finding may indicate an upper cervical lesion ⁽³⁰⁾.

In conclusion, SEPs in patients with cervical radiculopathy are more sensitive in detecting subtle posterior column dysfunction, which is

not at least detectable on routine NCS. SEP testing is a crucial complementary diagnostic technique for electrophysiologically assessing the function of the spinal cord and nerve roots. When comparing the patient and control groups, the N13 and P14 components have the highest sensitivity and specificity.

Acknowledgement

The author would like to thank Dr. Ahmed Al-Atraqchi from Saad Al-Witry Hospital for Neurosurgeries, and Assistant Professor Dr. Ali F. Al-Saadi from the Department of Surgery, College of Medicine, Al-Nahrain University for examining and referring patients with cervical radiculopathy. Also the author thanks Professor Dr. Farqad B. Hamdan from the Department of Physiology, College of Medicine, Al-Nahrain University for helping with the statistical analysis.

Conflict of interest

The author declares that they have no competing interests.

Funding

This research did not receive any specific grant from funding agencies in the public, commercial, or not-for-profit sectors..

References

1. George D, Campbell L, Marra J. Diagnostic uncertainty in cervical radiculopathy. *Mil Med.* 2022; usac239. doi: 10.1093/milmed/usac239.
2. Hakimi K, Spanier D. Electrodiagnosis of cervical radiculopathy. *Phys Med Rehabil Clin N Am.* 2013; 24(1): 1-12. doi: 10.1016/j.pmr.2012.08.012.
3. Nardone R, Höller Y, Brigo F, et al. The contribution of neurophysiology in the diagnosis and management of cervical spondylotic myelopathy: a review. *Spinal Cord.* 2016; 54(10): 756-66. doi: 10.1038/sc.2016.82.
4. Badhiwala JH, Ahuja CS, Akbar MA, et al. Degenerative cervical myelopathy - update and future directions. *Nat Rev Neurol.* 2020; 16(2): 108-24. doi: 10.1038/s41582-019-0303-0.
5. Sarwan G, De Jesus O. Electrodiagnostic evaluation of cervical radiculopathy. [Updated 2023 Aug 23]. In: StatPearls [Internet]. Treasure Island (FL): StatPearls Publishing; 2024. Available from: <https://www.ncbi.nlm.nih.gov/books/NBK563152/>.
6. Bono CM, Ghiselli G, Gilbert TJ, et al. An evidence-based clinical guideline for the diagnosis and treatment of cervical radiculopathy from

- degenerative disorders. *Spine J.* 2011; 11(1): 64-72. doi: 10.1016/j.spinee.2010.10.023.
7. Tavee J. Nerve conduction studies: Basic concepts. *Handb Clin Neurol.* 2019; 160: 217-24. doi: 10.1016/B978-0-444-64032-1.00014-X.
 8. Jerath N, Kimura J. F wave, A wave, H reflex, and blink reflex. *Handb Clin Neurol.* 2019; 160: 225-39. doi: 10.1016/B978-0-444-64032-1.00015-1.
 9. Fisher MA. Electrophysiology of radiculopathies. *Clin Neurophysiol.* 2002; 113(3): 317-35. doi: 10.1016/s1388-2457(02)00018-4.
 10. Manzano GM, Mangini N, Pereira Giuliano LM. Potenciais evocados cerebrais. In: Nóbrega JAM, Manzano GM (eds). *Manual de eletroneuromiografia e potenciais evocados cerebrais para a prática clínica.* São Paulo (SP): Atheneu; 2007. p. 51-65.
 11. Muzyka IM, Estephan B. Somatosensory evoked potentials. *Handb Clin Neurol.* 2019; 160: 523-40. doi: 10.1016/B978-0-444-64032-1.00035-7.
 12. Imam M, Hassan M. Spinal N13 versus cortical N20 and dermatomal somatosensory evoked potential studies in patients with cervical radiculopathy. *Alexandria J Med.* 2013; 49(4): 293-98. doi: <https://doi.org/10.1016/j.ajme.2013.03.002>
 13. Preston DC, Shapiro BE. *Electromyography in neuromuscular disorders. Clinical-electrophysiologic correlations.* 4th ed. Elsevier; 2020. p. 107-14, 124-8.
 14. Kimura J. *Electrodiagnosis in diseases of nerve and muscle: principles and practice.* 3rd ed. Philadelphia: Davis; 2013.
 15. Nuwer MR, Aminoff M, Desmedt J, et al. IFCN recommended standards for short latency somatosensory evoked potentials. Report of an IFCN committee. *International Federation of Clinical Neurophysiology. Electroencephalogr Clin Neurophysiol.* 1994; 91(1): 6-11. doi: 10.1016/0013-4694(94)90012-4.
 16. Cracco RQ. Scalp-recorded potentials evoked by median nerve stimulation: Subcortical potentials, travelling waves and somatomotor potentials. In: Desmedt JE (ed). *Clinical uses of cerebral, brainstem and spinal somatosensory evoked potentials.* New York: Karger; 1980. p. 1-26.
 17. Kelsey JL, Githens PB, Walter SD, et al. An epidemiological study of acute prolapsed cervical intervertebral disc. *J Bone Joint Surg Am.* 1984; 66(6): 907-14. doi: 10.2106/00004623-198466060-00011.
 18. Radhakrishnan K, Litchy WJ, O'Fallon WM, et al. Epidemiology of cervical radiculopathy. A population-based study from Rochester, Minnesota, 1976 through 1990. *Brain.* 1994; 117 (Pt 2): 325-35. doi: 10.1093/brain/117.2.325.
 19. Rhee JM, Yoon T, Riew KD. Cervical radiculopathy. *J Am Acad Orthop Surg.* 2007; 15(8): 486-94. doi: 10.5435/00124635-200708000-00005.
 20. Iyer S, Kim HJ. Cervical radiculopathy. *Curr Rev Musculoskelet Med.* 2016; 9(3): 272-80. doi: 10.1007/s12178-016-9349-4.
 21. Childress MA, Becker BA. Nonoperative management of cervical radiculopathy. *Am Fam Physician.* 2016; 93(9): 746-54.
 22. Tsao B. The electrodiagnosis of cervical and lumbosacral radiculopathy. *Neurol Clin.* 2007; 25(2): 473-94. doi: 10.1016/j.ncl.2007.02.001.
 23. Li JM, Tavee J. Electrodiagnosis of radiculopathy. *Handb Clin Neurol.* 2019; 161: 305-16. doi: 10.1016/B978-0-444-64142-7.00056-4.
 24. Hüllemann P, von der Brélie C, Manthey G, et al. Laser-evoked potentials in painful radiculopathy. *Clin Neurophysiol.* 2017; 128(11): 2292-9. doi: 10.1016/j.clinph.2017.09.100.
 25. Yue Q, Hale T, Knecht A. A Comparison of interside asymmetries of lower extremity somatosensory evoked potentials in anesthetized patients with unilateral lumbosacral radiculopathy. *Asian Spine J.* 2017; 11(1): 99-104. doi: 10.4184/asj.2017.11.1.99.
 26. Zileli M, Borkar SA, Sinha S, et al. Cervical spondylotic myelopathy: Natural course and the value of diagnostic techniques -WFNS Spine Committee Recommendations. *Neurospine.* 2019; 16(3): 386-402. doi: 10.14245/ns.1938240.120.
 27. Buchner H, Ferbert A, Brückmann H, et al. The subcortical generated somatosensory evoked potentials in non-cephalic, cephalic, and anterior neck referenced recordings in a patient with a cervico-medullary lesion: a clue to the identification of the P14/N14 and N13 generators. *J Neurol.* 1987; 234(6): 412-5. doi: 10.1007/BF00314087.
 28. Hume AL, Cant BR. Conduction time in central somatosensory pathways in man. *Electroencephalogr Clin Neurophysiol.* 1978; 45(3): 361-75. doi: 10.1016/0013-4694(78)90188-8.
 29. Aly FM, Khidre E, Mustafa NM. Early detection of cervical myelopathy in some rheumatic diseases using somatosensory and motor evoked potentials. *Egypt Rheumatol Rehab.* 2003; 30(6): 777-92.
 30. Manguire F, Courjon J. The origin of short latency somatosensory evoked potential in human. *Ann Neurol.* 1981; 9(6): 607-11. doi: <https://doi.org/10.1002/ana.410090616>.

E-mail: huseinghani@gmail.com,
huseinghani@colmed.nahrainuniv.iq

Received Sep. 28th 2023

Accepted Oct. 16th 2023