

Immunohistochemical Expression of CD133 in Ovarian Surface Epithelial Tumors

Samar A. Al-Shami¹ MSc, Ban J. Qasim¹ PhD, Sahira H. Alzubaidi² PhD

¹Dept. of Pathology and Forensic Medicine, College of Medicine, Al-Nahrain University, Baghdad, Iraq, ²Dept. of Pathology, Teaching laboratories of Medical City, Baghdad, Iraq

Abstract

- Background** The identification of antigenic profile of the cancer stem cells might have relevant clinical implication as they're able to proliferate and self-renew, in turn sustaining tumor growth. CD133 is one of robust surface marker for cancer stem cells in various neoplastic human tissues, including ovaries. It is associated with the clinical outcome of patients.
- Objective** To assess the immunohistochemical expression of cancer stem cell marker (CD133) in ovarian surface epithelial tumors.
- Methods** This study included a total of 100 ovarian tissue paraffin blocks, 70 tissue paraffin blocks included ovarian tumors obtained from patient who underwent total abdominal hysterectomy and bilateral salpingo-oophorectomy, while 30 tissue paraffin blocks assigned as the control group included normal ovarian tissue and fallopian tubes tissue. From each paraffin block, 2 sections were taken, one was stained with hematoxylin and eosin stain and the other section was stained immunohistochemically for CD133.
- Results** CD133 showed a high significant difference in its immunohistochemical expression between the control group and the case groups with the highest expression seen in malignant ovarian surface epithelial tumors ($P < 0.001$). CD133 expression was highly significantly associated with histopathological type ($P < 0.001$). CD133 also showed a significant relation to age ($r = 0.254$, $P = 0.034$), tumor grade ($r = 0.794$, $P < 0.001$), tumor stage ($r = 0.543$, $P = 0.013$) and presence of ascites ($P < 0.001$).
- Conclusion** CD133 expression revealed a highly significant differences in the ovarian surface epithelial tumors tissues compared to control group, which reflect its important role in ovarian carcinogenesis.
- Keywords** Ovarian surface epithelial tumors, ovarian carcinoma, cancer stem cells, cancer stem cell marker, CD133, immunohistochemistry
- Citation** Al-Shami SA, Qasim BJ, Hassan AM. Immunohistochemical expression of CD133 in ovarian surface epithelial tumors. *Iraqi JMS*. 2018; 16(3): 308-318. doi: 10.22578/IJMS.16.3.10

List of abbreviations: CD133 = Cancer stem cell marker, CSCs = Cancer stem cells, EMT = Epithelial-mesenchymal transition, FIGO = Federation of gynecology and obstetrics, HGSC = High grade serous carcinoma, IL = Interleukin, LDH = Lactate dehydrogenase, LGSC = Low grade serous carcinoma, OCC = Ovarian clear cell carcinoma, STIC = Serous tubal intra-epithelial carcinoma, TCC = Transitional cell carcinoma, TICs = Tumor initiating cells, TNF- α = Tumor necrosis factor - alpha, VEGF = Vascular endothelial growth factor

Introduction

Ovarian cancer is one of the most common causes of gynecologic neoplasm. The high mortality rate in

women with ovarian cancer is due to its detection at advanced stages. Even though there have been improvements in surgical techniques and treatment options, five-year survival for ovarian cancer still remain at approximately 45% ⁽¹⁾. Ovarian cancer represents the sixth most commonly diagnosed cancer among women in the world, and causes more deaths per year than any other cancer of the female reproductive system ⁽²⁾. In Iraq,

ovarian tumors rank the 6th commonest cancer among females and constituted 4.1% according to latest published Iraqi Cancer Board Registry in 2011 ⁽³⁾.

Surface epithelial tumors represent about 90% of primary ovarian cancers they may be solid, cystic or mixture of both, may be benign, borderline or malignant ⁽⁴⁾. They are traditionally classified into four main histological subtypes: serous, endometrioid, clear cell and mucinous carcinoma. Serous ovarian carcinoma is account for ~70% of epithelial ovarian cancers from which, the high grade serous ovarian carcinoma (HGSOC) accounts for two-thirds of all ovarian cancer deaths making it, by far the most extensively studied ovarian carcinoma.5

Cancer stem cells (CSCs) are a class of pluripotent cells that have been observed in most types of solid and hematologic cancers. It has been shown to be involved in tumor development, cell proliferation, and metastatic dissemination, while possessing a capacity for sustained self-renewal, it exhibits resistance to chemotherapy and radiotherapy ⁽⁶⁾. The first time in which the presence of cancer stem cells (CSCs) in ovarian cancer was confirmed is in a multilayered spheroid cells that had been isolated from patient ascites and subsequently verified in a mouse model using side population phenotype ⁽⁷⁾. It has been found that epithelial-ovarian cancer stem cells (EOC stem cells) are the source of metastatic progenitor cells through a differentiation process involving epithelial-mesenchymal transition (EMT) and mesenchymal-epithelial transition (MET) ⁽⁸⁾.

CD133 (prominin-1), a 5-transmembrane glycoprotein that has been used as a stem cell marker in various normal and neoplastic human tissues, including the ovary. CD133 expression as a putative marker for cancer stem cells in human malignant tumors, including ovarian cancer, may define a subpopulation of tumor-initiating cells and is associated with the clinical outcome of patients. However, its clinical significance in

ovarian cancer remains uncertain at this time ⁽⁹⁾. Ferrandina et al. first indicate that CD133 may be a marker of ovarian CSC through analyzing the expression of CD133 in 41 ovarian tumors, 8 normal ovaries, and 5 benign ovarian tumors. They found that primary ovarian cancer CD133+CK7+ cells had greater colony forming potential and had a higher proliferative potential than CD133-CK7+ cells ⁽¹⁰⁾.

This study aimed to assess the immunohistochemical expression of cancer stem cell marker (CD133) in ovarian surface epithelial tumors (benign, borderline, malignant tumors) and its correlation to clinicopathological parameters, which may reflect CD133 important role in ovarian carcinogenesis, migration, invasion and tumorigenic ability of ovarian cancer cells.

Methods

A retrospective study was intended, which included a total of 100 ovarian tissue paraffin blocks. Seventy tissue paraffin blocks were assigned as the case group included ovarian tumors obtained from patient who underwent total abdominal hysterectomy and bilateral salpingo-oophorectomy for malignant tumors, and ovarian cystectomy for benign tumors. These blocks were collected from Teaching Laboratories of Medical City, Al-Yarmook Teaching Hospital and private laboratories from January 2015 to April 2017. Thirty tissue paraffin blocks were assigned as the control group included normal ovarian tissue, inclusion cysts, corpus luteal cysts, follicular cysts, endometriosis (chocolate cyst), and fallopian tubes tissue, these blocks were collected from Medical City, Teaching Laboratories from November 2016 to January 2017.

The clinico-pathological parameters including (age of patient, ascites, tumor type, and tumor grade and tumor stage) were obtained from patients' admission case sheets and pathology reports.

From each paraffin block, 2 sections were taken, each of 5 µm thickness. One section was stained with the routine hematoxylin and eosin

stain and the histopathological diagnosis, tumor histological type and grade according to FIGO system were revised by a pathologist⁽¹¹⁾. The other section was deparaffinized and rehydrated at room temperature, antigen retrieval by antigen retrieval citrate buffers pH 6.0 [DAKO, Denmark] was carried out by microwave 1x10 min then allowed to cool for 20 min. Mouse monoclonal CD133 (MBS415235) (MyBioSource, USA) (dilution 1:200) applied to sections and were incubated for an overnight. Expose mouse and rabbit specific HRP/DAB detection immunohistochemistry kit (ab80436) (Abcam, UK) reagents was used⁽¹²⁾. Counterstaining of the sections by Mayer's Hematoxylin stain for 20-30 seconds then followed by mounting of the sections by using Roti®-Mount Aqua (ROTH, Germany) followed by glass coverslip. Technical negative control was done by the omission of Anti- CD133 antibody.

Interpretation of immunohistochemistry staining and quality control for CD133

Apical or diffuse cytoplasmic and membranous brown staining of the ovarian epithelial tumor cells was taken as positive results^(13,14). A tissue section of colorectal adenocarcinoma was taken as a positive quality control tissue, while by omission of primary antibody technical negative control was obtained. The immunohistochemical expression of CD133 positivity was analyzed in a semi-quantitative scheme as following:

A. The intensity: the intensity of positivity was scored as follows:

- 0: no staining,
- 1: weak,
- 2: moderate,
- 3: strong.

B. The percentage: The extent of positivity was scored according to the percentage of cells showing positive staining as follows:

- <10% is 1;
- 11%-50% is 2;
- 51%-75% is 3;
- >75% is 4.

Then the intensity and the percentage of positivity scores were multiplied to obtain the final score, a range from 0 to 12 obtained. the scores >1 were considered as positive⁽¹⁴⁾.

Statistical analysis

Numerical data were presented as mean \pm standard error, unpaired t-test was used to compare means between two groups while analysis of variance (ANOVA) was used in case if number of groups was more than two. Categorical data were presented as number and percentage. the comparison of number between different groups was done using Fisher exact test and chi square test. Pearson correlation was done between different parameters and presented as r (correlation coefficient) and p value (level of significance). P value < 0.05 was considered significant.

The software used was Microsoft excel 2016 and SPSS (statistical package for social sciences) version 23.

Results

According to frequency of the positive and negative expression of cancer stem cell marker CD133 in case and control groups, there is a highly statistically significant difference in CD133 expression between the control group and the case group with highest expression in the malignant ovarian surface epithelial tumors (P < 0.001) (Table 1).

According to semiquantitative scoring system, the control group showed the lowest immunohistochemical expression of CD133 (Mean = 0.2, SE = 0.11). While the ovarian surface epithelial tumors scoring showed higher results, in which malignant ovarian surface epithelial tumors showed the highest immunohistochemical expression of CD133 (Mean = 10.25, SE = 0.55), the borderline tumors immunohistochemical expression of CD133 was (Mean = 2.87, SE = 0.25) and the benign tumors showed the lowest immunohistochemical expression of CD133 among the ovarian surface epithelial tumors (Mean = 0.25, SE = 0.12) (Table 2). According to that, there is a highly significant difference in

the immunohistochemical expression of CD133 between the case and control groups with the highest scores seen in malignant ovarian surface epithelial tumors ($P < 0.001$) (Table 2).

Table 1. Frequency of the positive and negative expression of cancer stem cell marker CD133 in case and control groups

Marker	Expression	Control No. (%)	Benign No. (%)	Borderline No. (%)	Malignant No. (%)	P value
CD133	Positive	3 (10.0)	1 (5.0)	29 (96.7)	20 (100)	< 0.001**
	Negative	27 (90.0)	19 (95.0)	1 (3.3)	0 (0.0)	

** : high statistically significant

Table 2. Immunohistochemical expression of CD133 according to the semiquantitative scoring in case and control groups

Marker	Control N=30 Mean±SE	Benign N=20 Mean±SE	Borderline N=30 Mean±SE	Malignant N=20 Mean±SE	P value
CD133	0.2±0.11	0.25±0.12	2.87±0.25	10.25±0.55	< 0.001**

** : high statistically significant

CD133 showed a highly significant difference in the expression in relation to histopathological type ($P < 0.001$) and in malignant ovarian epithelial tumors regardless their histopathological types ($P < 0.001$) (Table 3). Among the 70 cases of ovarian epithelial tumors collected during the study, papillary serous cystadeno-carcinoma and serous adenocarcinoma showed the highest immunohistochemical expression score of CD133 (Mean = 11.3, SE = 0.47) (Figure 1), followed by other histopathological subtypes [endometrioid adenocarcinoma (Figure 2), malignant Brenner tumors, clear cell carcinoma, and transitional cell carcinoma], then the mucinous cystadenocarcinoma was with (Mean = 6.75, SE = 1.11) (Figure 3). CD133 expression in borderline tumors was lower in serous tumors (Mean = 3.05, SE =

0.33) (Figure 4), mucinous (Mean = 2.0 , SE = 0.0) (Figure 5), and other histological subtypes (Mean = 3.5 , SE = 0.96). Benign tumors showed the lowest CD133 expression while benign mucinous cystadenoma showed negative expression of CD133 (Figure 6, Table 3).

Regarding other clinicopathological parameters, CD133 showed a significant relation between its expression and increase of the age ($r = 0.254$, $P = 0.034$), highly significant relation with the increment of tumor grade ($r = 0.794$, $P < 0.001$). CD133 showed a significant relation between its expression and tumor stage ($r = 0.543$, $P = 0.013$) (Table 4).

Also, a significant relation of CD133 expression with the presence of ascites ($P < 0.001$) was found (Table 5).

Table 3. Score of the immunohistochemical expression of cancer stem cell marker CD133 in relation to histopathological type of ovarian surface epithelial tumors

Histopathology	Benign Mean±SE	Borderline Mean±SE	Malignant Mean±SE	P value
Serous	0.1±0.1	3.05±0.33	11.3±0.47	< 0.001 **
Mucinous	0.0±0.0	2.0±0.0	6.75±1.11	< 0.001 **
Others	0.67±0.33	3.5±0.96	10.83±0.75	< 0.001 **
P value	0.074 ^{NS}	0.140 ^{NS}	0.001 *	

** : high statistically significant, NS: Non-statistically significant. Others = Endometrioid tumors, Brenner tumors, clear cell tumors, and transitional carcinoma

Table 4. Relation of CD133 score with age, tumor grading, staging

Parameter	CD133 score	
	r	P
Age (years)	0.254	0.034 *
Tumor grade (FIGO)	0.794	< 0.001**
Tumor stage (FIGO)	0.543	0.013 *

*: statistically significant **: high statistically significant

Table 5. Relation of CD133 immunohistochemical scores with presence of ascites

Marker	Ascites		P value
	Positive N=33 Mean±SE	Negative N=37 Mean±SE	
CD133 score	6.3±0.82	2.38±0.47	< 0.001**

** : high statistically significant

Discussion

In the present study, all the malignant tumors showed 100% positive expression for CD133 marker, 96.7% of borderline tumors showed positive expression, and only 5.0% of benign tumors showed positive expression for CD133. For the control group; only 10.0% showed positive expression for CD133. Also, according to semiquantitative scoring system, the control group showed the lowest immunohistochemical expression of CD133. While the ovarian surface epithelial tumors scoring showed higher results, in which malignant ovarian surface epithelial tumors showed the highest expression of CD133. According to that, there is a highly significant difference in the expression of CD133

according to the semiquantitative scoring between the control and case groups with the highest expression in malignant ovarian surface epithelial tumors (P < 0.001). This study was parallel to Ferrandina et al. an Italian study in which there was significant difference in CD133 expression among control group, benign ovarian tumors compared to malignant ovarian tumors⁽¹⁰⁾. Also parallel to Korean study performed by Kim et al. which compared CD133 expression in benign, borderline, and malignant tumors, and found that the expression levels of CD133 was significantly increased in cancer, compared with benign tumors and borderline tumors with P = 0.00064⁽¹⁵⁾.

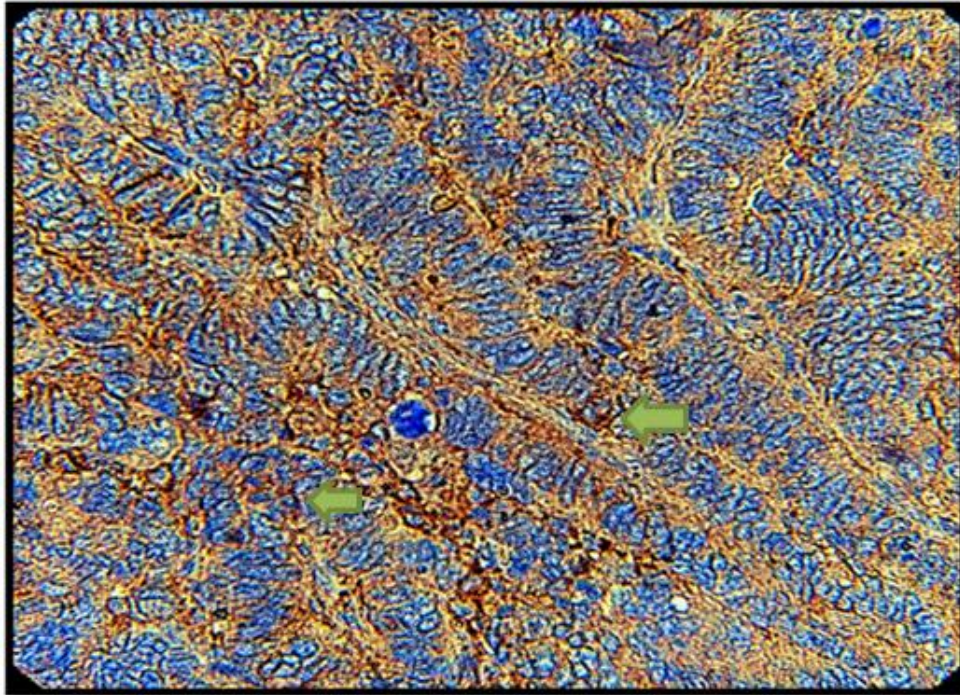


Figure 1. Serous adenocarcinoma (FIGO grade III) tissue section showing positive immunohistochemical diffuse brown cytoplasmic and membranous expression of CD133 monoclonal antibody of > 75% epithelial cells with strong intensity and score of 12 (arrows) (40×)

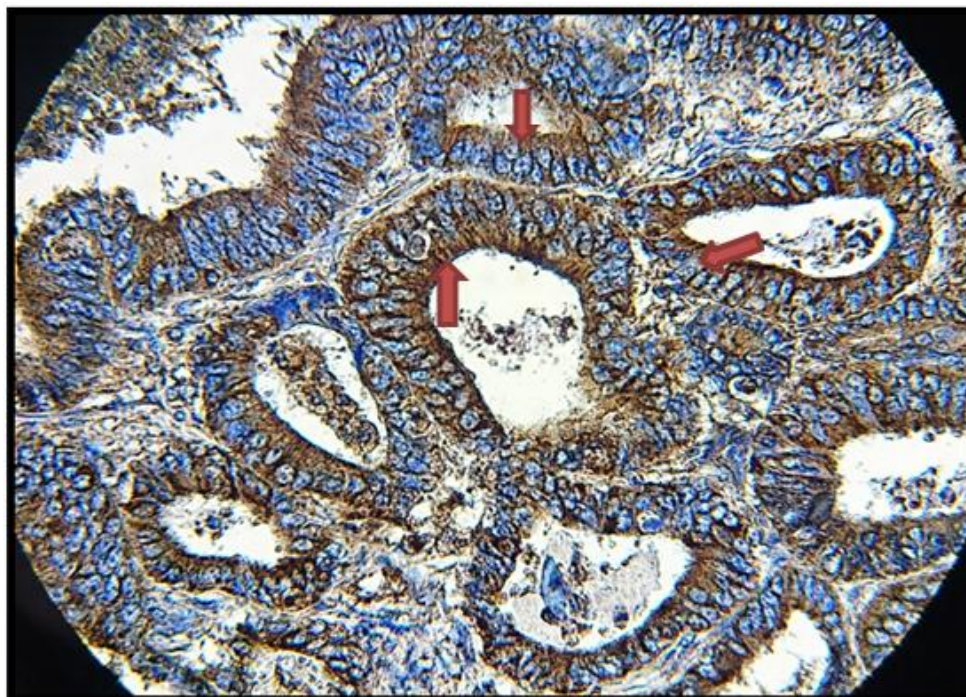


Figure 2. Endometrioid adenocarcinoma (FIGO grade I) tissue section showing positive immunohistochemical diffuse brown cytoplasmic and membranous expression of CD133 monoclonal antibody of 70% epithelial cells with strong intensity and score of 9 (arrows) (40×)

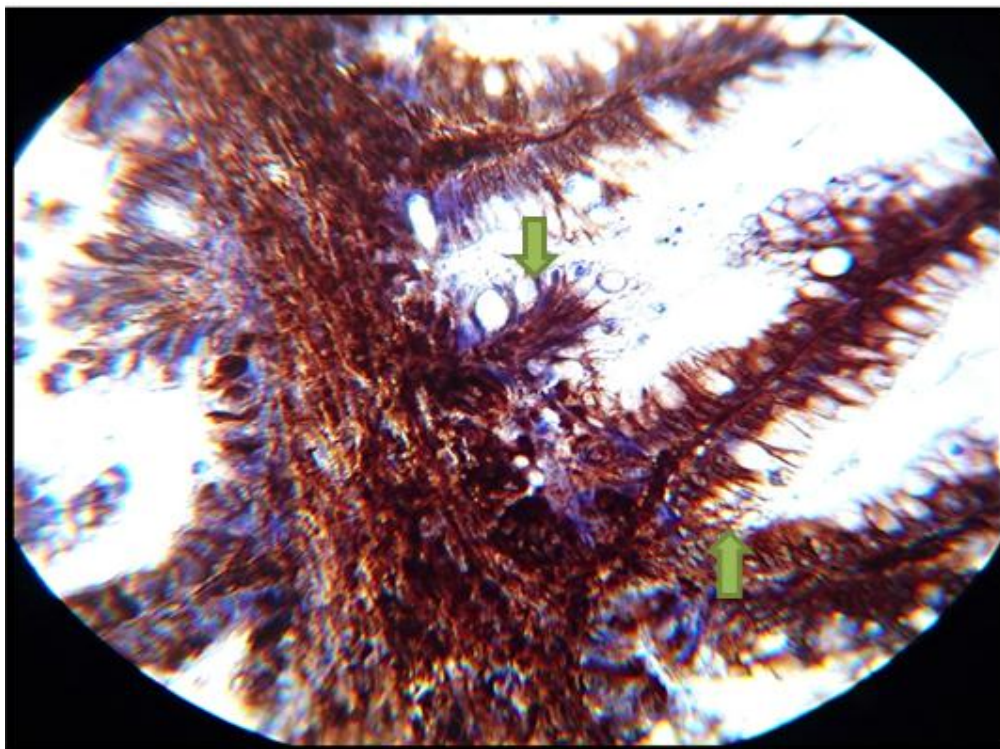


Figure 3. Mucinous adenocarcinoma (FIGO grade I) tissue section showing positive immunohistochemical diffuse brown cytoplasmic and membranous expression of CD133 monoclonal antibody of 60% epithelial and stromal cells with strong intensity and score of 9 (arrows) (40×)

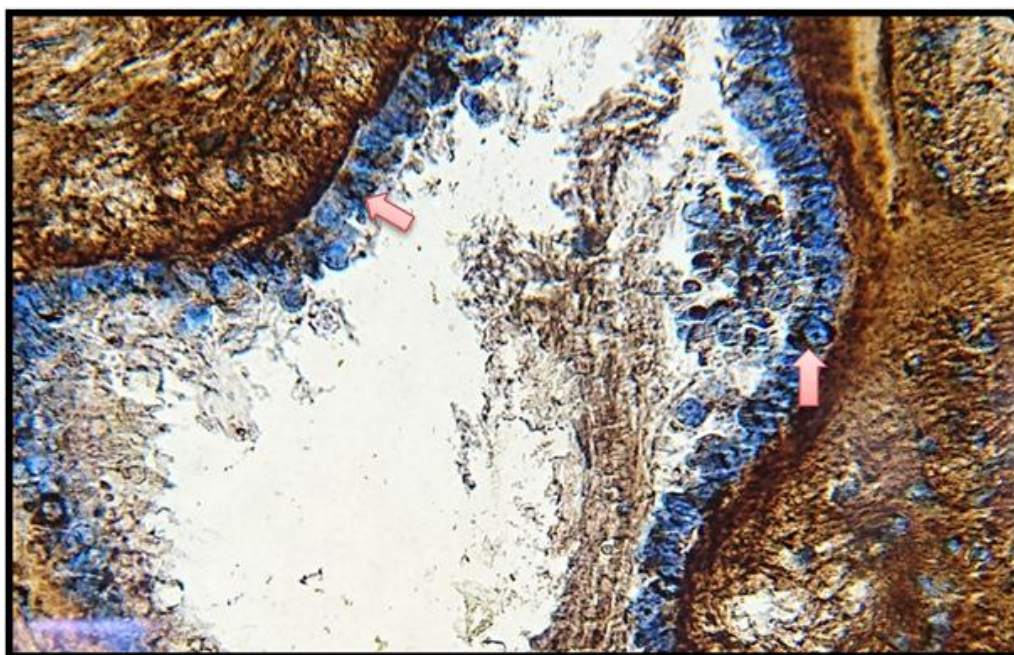


Figure 4. Borderline serous tumor tissue section showing positive immunohistochemical diffuse brown cytoplasmic and membranous expression of CD133 monoclonal antibody of 50% epithelial cells with moderate intensity and score of 4 (arrows) (40×)

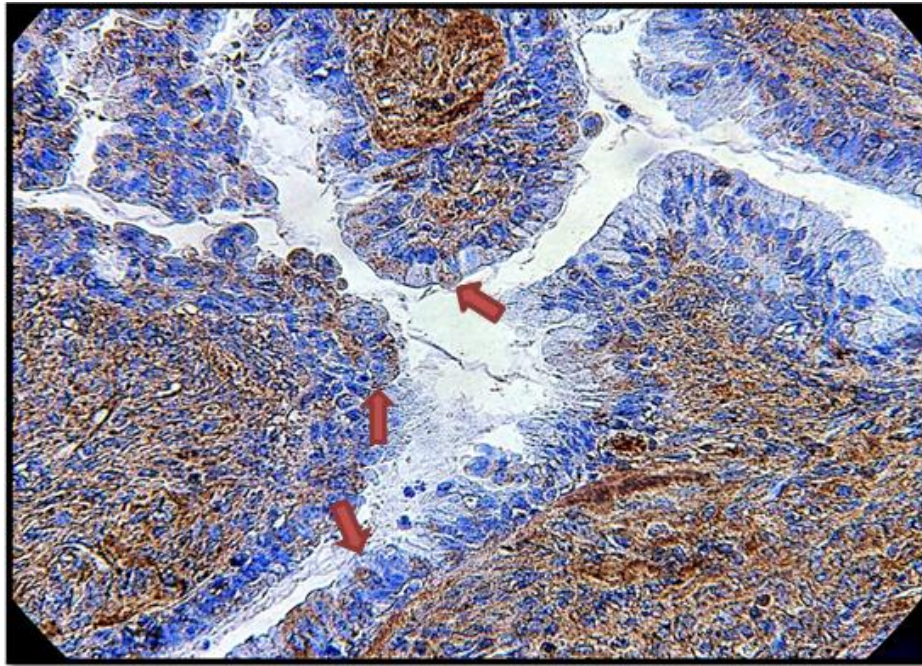


Figure 5. Borderline mucinous tumor tissue section showing positive immunohistochemical diffuse brown cytoplasmic expression of CD133 monoclonal antibody of 50% epithelial cells with moderate intensity and score of 4 (arrows) (40×)

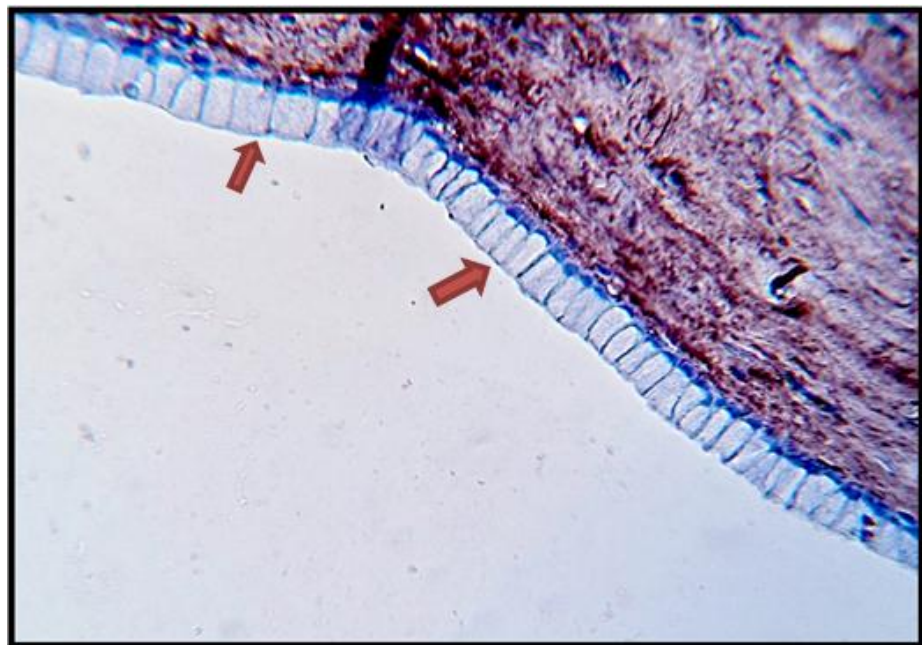


Figure 6. Benign mucinous cystadenoma tissue section showing negative immunohistochemical expression of CD133 monoclonal antibody of the epithelial (arrows) (40×)

Among the 70 cases collected during this study; papillary serous cystadenocarcinoma and serous adenocarcinoma showed the highest immunohistochemical expression of CD133 followed by other histopathological subtypes (endometrioid adenocarcinoma, malignant brenner tumors, clear cell carcinoma, and transitional cell carcinoma), then the mucinous cystadenocarcinoma, so there is a highly significant difference in the immunohistochemical expression of CD133 relation to histopathological type ($P < 0.001$) and highly significant relation between immunohistochemical expression of CD133 and malignant tumors regardless the histopathological types ($P < 0.001$). These results are in agreement with Zhang et al. a study, which demonstrated that CD133 expression was found in 32% HGSC, 27% LGSC, 9% endometrioid carcinoma, 32% consists of mucinous carcinoma, clear cell carcinoma, transitional cell carcinoma and others and found that there is significant correlation between expression of CD133 with histological type specially serous carcinoma ($P = 0.035$)⁽⁹⁾. Also parallel to a study performed by Ruscito et al. which showed that about 49.1% of primary ovarian high-grade serous adenocarcinomas were CD133+⁽¹⁶⁾.

Regarding the relation of CD133 immunohistochemical expression semiquantitative scoring and age during the current study, among the 70 cases of ovarian surface epithelial tumors, there is a statistically significant relation between the immunohistochemical expression of CD133 score and increase of the age ($r = 0.254$ and $P = 0.034$). Kim et al. found that the expression levels of CD133 didn't vary by age in benign tumors, borderline tumors, and cancer, however in the cancer samples, the expression levels were significantly increased among the oldest age group⁽¹⁵⁾. Also, the Chinese meta-analytic study performed by Zhou et al. on prognostic value of CD133 in ovarian cancer, mentioned that there is no correlation between CD133 expression and patients' age⁽¹⁷⁾, the differences among the current study, Kim et al. and Zhou et al. may attributed to

differences in the population sample size, time quality, different study technique.

Regarding the relation of CD133 immunohistochemical expression and tumor grade, among the 20 cases of ovarian surface epithelial malignant tumors, there is highly significant relation between the immunohistochemical expression of CD133 and the increment of tumor grade ($r = 0.794$ and $P < 0.001$). This data reflects the following; on the increment of CD133 expression there is increase of the loss of differentiation or increase of tumor grade, this suggest the high tumorigenicity of CD133. These findings were opposite to Zhou et al. study, which mentioned that there is no correlation between CD133 expression and tumor grade⁽¹⁷⁾ the Romanian study performed by Onisim et al. on expression of CD133, found that CD133 expression in ovarian tumor cells was not significantly associated with the tumor grade ($p > 0.05$)⁽¹⁸⁾. The differences among current study, Onisim et al. study and Zhou et al. study may be attributed to Sample size and quality, geographical areas differences, focusing on specific histological type, different study technique.

Regarding the relation of CD133 expression and tumor stage, among the 20 cases of ovarian surface epithelial malignant tumors, there is a statistically significant relation between the immunohistochemical expression of CD133 and increase of tumor stage ($r = 0.543$ and $P = 0.013$). This study was in agreement with Ricci et al. study, which mentioned that overexpression of CD133 may correlates with the tumor stage and with a reduced 2-year survival. However, CD133 were variably expressed resulting in absence of significant correlation, this may be attributed to their sample population, as the number of patients were too small⁽¹⁹⁾. Kim et al. showed that there is significant correlation of CD133 expression to ovarian tumor stage, in which CD133 was increased in stage IV compared with stage I⁽¹⁵⁾.

Regarding the relation of CD133 immunohistochemical expression semiquantitative scoring and presence of ascites, there is statistically significant relation

between the expression of CD133 and presence of ascites with $P < 0.001$. The results of present study were in agreement with Zhang et al. study, which found that CD133 expression among the ovarian epithelial carcinoma cases, there is a significant correlation between expression of CD133 with presence of ascites ($P = 0.010$)⁽⁹⁾. While opposite to Onisim et al. study which found that CD133 expression in ovarian tumor cells was not significantly associated with the presence of malignant ascites ($p > 0.05$)⁽¹⁸⁾. The differences between current study and Onisim et al. study may be attributed to sample size and quality, focusing on specific histological type, different study technique.

In conclusion CD133 revealed a highly significant differences in the expression of ovarian surface epithelial tumors tissues compared to control group, which reflect its important role in ovarian carcinogenesis through enhancement of migration, invasion and tumorigenic ability of ovarian cancer cells. The association of cancer stem cells marker CD133 expression with various ovarian epithelial histopathological types, higher tumor grade, and the association with the presence of ascites may indicate that CD133 expression may have a role in tumor cells proliferation and invasion which in turn show potential clinical value in the predicting disease progression or prognosis in ovarian epithelial cancer, supporting the proposed link between CD133 and cancer stem cells. The significant relation between the expression of CD133 and the increase of the age in patients with ovarian surface epithelial tumors may indicate that old age associates with later stage and higher-grade tumor, which in turn carry poor survival of these patients, this may attribute to the potential biologic and molecular difference among various age groups in ovarian epithelial tumors.

Acknowledgments

Authors are thankful to everyone associated with this work starting from the staff of Laboratory of Pathology Department in the Medical College of Al-Nahrain University and ending with all Doctors & staff of Teaching

Laboratories of Medical City, Al-Yarmook Teaching Hospital for their valuable support and advice.

Authors' contribution

Dr. Al-Shami collected the cases data, performed the routine H&E and the immunohistochemical technique and analyzed the results of the study. Dr. Qasim helped in study design and supervising the work. Dr. Alzubaidi participated in the collection of cases and revision of histopathological sections.

Conflict of interest

The authors declare no conflict of interest.

Funding

The research working funding was provided by the authors.

References

1. Mahmood F, Kadhim H, Al-Khuzae L. Expression of P53 protein in neoplastic and non neoplastic ovarian lesions. IRAQI J MED SCI. 2013; 11: 280-4.
2. Permuth-Wey J, Sellers T. Epidemiology of ovarian cancer. In: Verma M (ed). Cancer epidemiology: volume 2 modifiable factors. Switzerland: Springer Nature, Humana Press; 2009. p. 413-37. doi: 10.1007/978-1-60327-492-0_20.
3. Iraqi cancer registry 2011. Iraqi Ministry of Health. 2011. p. 1-10.
4. Abdul Ghany M, Khattab Y, Al-Kurtas M. Immunohistochemical expression of CD44v6 and P53 status in borderline and malignant ovarian surface epithelial tumors. A clinico-pathologic study. Iraqi JMS. 2016; 14: 7-14.
5. Domcke S, Sinha R, Levine D, et al. Evaluating cell lines as tumour models by comparison of genomic profiles. Nat Commun. 2013; 4: 2126. doi: 10.1038/ncomms3126.
6. Chang JC. Cancer stem cells: role in tumor growth, recurrence, metastasis, and treatment resistance. Medicine (Baltimore). 2016; 95(1 Suppl 1): S20-5. doi: 10.1097/MD.0000000000004766.
7. Gao MQ, Choi YP, Kang S, et al. CD24+ cells from hierarchically organized ovarian cancer are enriched in cancer stem cells. Oncogene. 2010; 29(18): 2672-80. doi: 10.1038/onc.2010.35.
8. Yin G, Alvero A, Craveiro V, et al. Constitutive proteasomal degradation of TWIST-1 in epithelial-ovarian cancer stem cells impacts differentiation and metastatic potential. Oncogene. 2013; 32(1): 39-49. doi: 10.1038/onc.2012.33.
9. Zhang J, Guo X, Chang DY, et al. CD133 expression associated with poor prognosis in ovarian cancer.

- Mod Pathol. 2012; 25(3): 456-64. doi: 10.1038/modpathol.2011.170.
10. Ferrandina G, Bonanno G, Pierelli L, et al. Expression of CD133-1 and CD133-2 in ovarian cancer. *Int J Gynecol Cancer*. 2008; 18(3): 506-14.
 11. Colombo N, Peiretti M, Parma G, et al. Newly diagnosed and relapsed epithelial ovarian carcinoma: ESMO clinical practice guidelines for diagnosis, treatment and follow-up. *Ann Oncol*. 2010; 21 Suppl 5: v23-30. doi: 10.1093/annonc/mdq244.
 12. Abcam. EXPOSE mouse and rabbit specific HRP/DAB detection IHC kit (ab80436). 2016: 1-3.
 13. Curley M, Therrien V, Cummings C, et al. CD133 expression defines a tumor initiating cell population in primary human ovarian cancer. *Stem Cells*. 2009; 27(12): 2875-83. doi: 10.1002/stem.236.
 14. Shiwu W, Lan Y, Danna W, et al. Aberrant expression of CD133 in non-small cell lung cancer and its relationship to vasculogenic mimicry. *BMC Cancer*. 2012; 12: 535. doi: 10.1186/1471-2407-12-535.
 15. Kim KH, Kang YJ, Jo JO, et al. DDX4 (DEAD box polypeptide 4) colocalizes with cancer stem cell marker CD133 in ovarian cancers. *Biochem Biophys Res Commun*. 2014; 447(2): 315-22. doi: 10.1016/j.bbrc.2014.03.144.
 16. Ruscito I, Cacsire D, Vergote I, et al. Exploring the clonal evolution of CD133/aldehyde-dehydrogenase-1 (ALDH1)-positive cancer stem-like cells from primary to recurrent high-grade serous ovarian cancer (HGSOC). a study of the ovarian cancer therapy-innovative models prolong survival (OCTIPS). *Eur J Cancer*. 2017; 79: 214-225. doi: 10.1016/j.ejca.2017.04.016.
 17. Zhou Q, Chen A, Song H, et al. Prognostic value of cancer stem cell marker CD133 in ovarian cancer: a meta-analysis. *Int J Clin Exp Med*. 2015; 8(3): 3080-8.
 18. Onisim A, Iancu M, Vlad C, et al. Expression of Nestin and CD133 in serous ovarian carcinoma. *JBUON*. 2016; 21(5): 1168-75.
 19. Ricci F, Bernasconi S, Porcu L, et al. ALDH enzymatic activity and CD133 positivity and response to chemotherapy in ovarian cancer patients. *Am J Cancer Res*. 2013; 3(2): 221-9.

Correspondence to Dr. Samar A. Al-Shami

E-mail: dr.samaralshami1@gmail.com

dr.samaralshami1@colmed-alnahrain.edu.iq

Received Nov. 14th 2017

Accepted Dec. 19th 2017