

# Morphometric analysis of odontoid process.

Hayder hammadi abdulameer MBChB; FICMS.

## **Abstract**

**Background:** The axis vertebra is the strongest cervical vertebrae; the characteristic feature of it is the presence of strong bony element, the dens (odontoid process). Several investigations have shown its relation with certain congenital anomalies.

**Objective:** The aim of this study was to evaluate the value of some morphometric parameters measured from the odontoid process of the axis vertebra to judge the degree of retroflexion of the odontoid process in relation to the morphological architecture.

**Method:** 30 randomly selected dry bones of adult second cervical vertebrae were used. These vertebrae were examined grossly and morphometrically, and the data obtained were analyzed by using global lab image/2 computer program.

**Results:** Morphometric results of this study showed that the retroflexion of the dens should

be related to dorsal deviation, if the anteroposterior distance of the dens is fixed. The thicker anteroposterior dens is longer, wider, but less dorsally deviated.

**Conclusion:** We may be able to consider the dorsally deviated dens and the anteroposterior thickness of the dens as indicator for the degree of retroflexion of the dens.

The study may elaborate the possibility of using the above parameters as markers for the retroflexion of dens in cases of Chiari I malformation. Thus a preliminary diagnosis could be achieved.

**Key words:** morphometry, dens, congenital anomaly.

IRAQI J MED SCI, 2010; VOL.8 (1): 57-65

## **Introduction**

Vertebra C2 is the strongest of the cervical vertebrae. C1, carrying the cranium, rotates on C2, as when a person turns the head. The axis has two large, flat bearing surfaces, the superior articular facets, on which the atlas rotates. The distinguishing feature of the axis is the blunt tooth-like dens (odontoid process), which projects superiorly from its body. Both the dens (G. tooth) and the spinal cord inside its coverings are encircled by the atlas. The dens lie anterior to the spinal cord and serves as the pivot about which the rotation occurs. The dens are held in position against the posterior aspect of the anterior arch of the atlas by the transverse ligament of the atlas<sup>(1)</sup>.

The axis, acts as an axle for rotation of the atlas and head around the strong dens (odontoid process), which projects cranially from the superior surface of the body.

The dens are conical in shape. It may be tilted a little, up to 14°, posteriorly, or, less often, anteriorly on the body of the axis: it may also tilt laterally up to 10°. The apex is pointed, and from this point arises the apical ligament. The anterior surface bears an ovoid articular facet for the anterior arch of the atlas<sup>(2)</sup>.

Anomalous development of the odontoid is uncommon, and its clinical significance lies in its potential for producing serious neurologic sequelae<sup>(3)</sup>. These anomalies include either odontoid invagination, in which the odontoid process bulges upward into the foramen magnum and compresses the brainstem without deformity of the occipital bone<sup>(4)</sup>, or Congenital and developmental osseous abnormalities and anomalies that affect the

Dept. human anatomy, college of medicine,  
Al-Nahrain University.

Address Correspondence to: Dr. Hayder H. Abdulameer,

E- mail: [hh\\_Abdulameer@yahoo.com](mailto:hh_Abdulameer@yahoo.com)

Received: 3<sup>rd</sup> December 2009, Accepted:  
28<sup>th</sup> April 2010.

craniocervical junction complex which can result in neural compression and vascular compromise and can manifest itself with abnormal cerebrospinal fluid dynamics<sup>(5)</sup>.

Chiari I malformations are often associated with congenital craniocervical anomalies, such as platybasia, basilar invagination, and retroflexion of the odontoid process<sup>(6)</sup>.

The aim of this study was to evaluate the values of some morphometric parameters measured from the odontoid process of the axis vertebra to judge the degree of retroflexion in relation to other morphological architectures.

### **Material and methods**

This study involves anatomical observation of 30 randomly selected dry bones of adult second cervical vertebrae obtain from anatomical museum of the department of human anatomy at Al- Nahrain College of medicine. The odontoid process of these vertebrae was examined grossly. Certain morphometric measurements were done on the following parameters:

- The line which connect the upper and lower point of the anterior surface of the body of the axis represented by L1 (figure1).
- The mid-line of the anterior surface of the dens is represented by L2 (figure 2).
- The angle between L1&L2 is called G1. This parameter could indicate the deviation of the anterior surface of dens from that of axis (figure 3).
- The point of deviation of L1 across L2 called P1 (figure 3).
- The most posterior point of the posterior surface of dens is P2(figure 3).
- D1 represents the distance of the horizontal imaginary line between the most posterior point of dens P2 and the L2 (figure3&4).

- D2 represents the distance between P2 and the linear upward extension of L1 (figure3&4).

- G2 represents the deduct value of D2 from D1 (Figure 4).

- The length of dens represents the line between the P1 and its highest apical point (figure 5).

- The width of the dens is widest anterior distance of the dens (figure 5).

Measurements were done on the photographs of the odontoid process of the second cervical vertebra, The photograph of the axis vertebra were done according to the need of experimental analysis of this study regardless of the anatomical position of the second cervical vertebrae. The data obtained from these measurements were analyzed using the global lab-image2 computer program

### ***Global lab image2 software:***

Is the keystone in this study by which all the results can be counted and analyzed manually or automatically (with less degree of user interference)<sup>(7)</sup>. The software is a product from (Data Translation Inc. USA). As any other software, it needs special requirements to be installed on the PC. These requirements are:

- MMX processor (Pentium III or higher).
- Microsoft® Windows 98, ME, or XP.
- At least 128 MB of random access memory (RAM).
- At least 150 MB of available hard disk space.
- CD-ROM drive.
- SVGA monitor.
- Display resolution set to 800x600 pixels or higher.
- Color quality set to highest (32-bit).
- Imaging device or frame grabber board (optional).

**Results**

The statistical analyses of the dens were as the following:

**The first group with significant relation ship these include:**

- The correlation between the measurements of the angle (G1) and the (G2) (figure 3, 4), the P value indicates highly significant relationship (table 1).
- The correlation between angle (G1) and the distance between anterior and posterior points of dens (D1) (figure 3, 4), the P value indicates significant relationship (Table 1).

- The correlation between (D1) and length (figure 4, 5), the P value indicates highly significant relationship (table2).

- The correlation between (D2) and the length (figure 4, 5), the P value indicates significant relationship (table2).

- The correlation between (D1) and (D2) (figure 3); the P value indicates significant relationship (table2).

- The correlation between (D2) and (G2) (figure 4); the P value indicates significant relationship (table2).

**Table 1: statistical analysis of this study**

| Type of relation ship          | Correlation coefficient (r2) | Significance (P) value | Notes                            |
|--------------------------------|------------------------------|------------------------|----------------------------------|
| Angle (G1)with (G2)*           | 0.872                        | 0.00001                | Highly significant relation ship |
| Angle (G1) with length*        | 0.001                        | 0.868                  | Non- significant relation ship   |
| Angle (G1) with side to side * | 0.015                        | 0.524                  | Non- significant relation ship   |
| Angle (G1) with D1#            | 0.136                        | 0.046                  | Significant relation ship        |
| Angle (G1) with D2*            | 0.313                        | 0.058                  | Non- significant relation ship   |

**The second group with non-significant relation ship these include:**

- The correlation between the measurements of the angle (G1) and the length (figure3, 5), the P value indicates non- significant relationship (Table 1).
- The correlation between the measurements of angle (G1) with (D2) (figure 3, 4), the P value indicates non-significant relationship (Table 1).
- The correlation between the measurements of length and G2 (figure5, 4), the P value indicates non- significant relationship (Table 2).

- The correlation between G2 and D1 (figure 4), the P value indicates non-significant relationship (Table 2).

- The correlation between side to side measurements (figure 5) and the angle G1, G2, D1, D2, and the length of dens (figure3, 4), the P value indicates non-significant relationship (Table 2).

**Table 2: statistical analysis of this study**

| Type of relation ship        | Correlation coefficient (r2) | Significance (P) value | Notes                            |
|------------------------------|------------------------------|------------------------|----------------------------------|
| D1 and length of dens*       | 0.419                        | 0.0001                 | Highly significant relation ship |
| D2 and length*               | 0.554                        | 0.006                  | Significant relation ship        |
| Side to side and length#     | 0.006                        | 0.697                  | Non- significant relation ship   |
| G2 and length *              | 0.192                        | 0.154                  | Non- significant relation ship   |
| G2 and D1#                   | 0.012                        | 0.73                   | Non- significant relation ship   |
| Anteroposterior (D1)and D2 * | 0.412                        | 0.024                  | Significant relation ship        |
| Side to side and D2*         | 0.01                         | 0.757                  | Non- significant relation ship   |
| G2 and D2 *                  | 0.477                        | 0.013                  | Significant relation ship        |
| Side to side and (D1) #      | 0.000                        | 0.961                  | Non- significant relation ship   |
| G2 and side to side*         | 0.005                        | 0.832                  | Non- significant relation ship   |

# Negative correlation (-) \*Positive correlation (+)

### Discussion

This study concerning with statistical analysis, and morphology with special emphasis on the degree of the inclination of the odontoid process, for functional and clinical manifestations, This inclination is important because The straight odontoid process is only subjected to stress of weight of the skull, but the dorsally inclined dens act to bending stress<sup>(8)</sup>.

The orientations of the parameters and the statistical analysis showed in this study support the view that had been adapted previously in the anomalous dens as a clinical significance in producing serious neurological squeal<sup>(3)</sup>. Although there are several recognized variations such as (aplasia, hypoplasia, and os odontoideum Congenital absence of the odontoid process, or Duplicated odontoid process),some anomalous may produces a serious clinical manifestations these may be associated with subluxation and neuraxial compression and atlantoaxial instability<sup>(9-11)</sup>,headaches, pseudotumor-like episodes and hydrocephalus<sup>(1)</sup>, or compression of the upper cervical cord<sup>(13)</sup>.

Chiari I malformations may be associated with changes that may be occurs in the cranio cervical region or herniation of the cerebellar tonsil below the foramen magnum <sup>(14)</sup>. In addition to that, this malformation is often associated with retroflexion of the odontoid process. These signs confirm prior reports of an increased incidence of Chiari I malformation.

In this study we emphasized on the correlation between the degrees of inclination (retroflexion) in relations with other statistical analysis of the odontoid process.

The line suggested being the anterior vertebral line of the axis vertebra L1 which used for measurements of the degree of angulations (figure 1) is unchanging when the axis vertebra changes from normal anatomical position.

The angle between L1&L2 (G1), this parameter could indicate the deviation of the anterior surface of dens from that of axis (figure 3).G2 represents the deduct value of D2 from D1 this parameter could indicate the dorsal deviation of the anterior surface of dens (L2) excluding its anteroposterior thickness (Figure 4).

There is a significant relationship with positive correlation between the degree of retroflexion (G1), and the dorsal deviation of the dens (G2), if the antero posterior distance of the dens is fixed so that the degree of retroflexion should be related to the dorsal deviation of the dens.

The significant relationship with negative correlation between retroflexion (G1), and antero posterior distance of the dens (D1), means that whenever the degree of retroflexion increases, the antero posterior distance (thickness) decreases, however there is a significant relationship with positive correlation between this anteroposterior thickness(D1), thickness with dorsally deviated (D2), and the length of the dens, there is a non-significant relationship between the length and the degree of retroflexion. This indicates that the longer dens is thicker anteroposterior, with more dorsally deviated. This positive correlation not related to the degree of retroflexion of the dens but it may be related to massive growth of the dens.

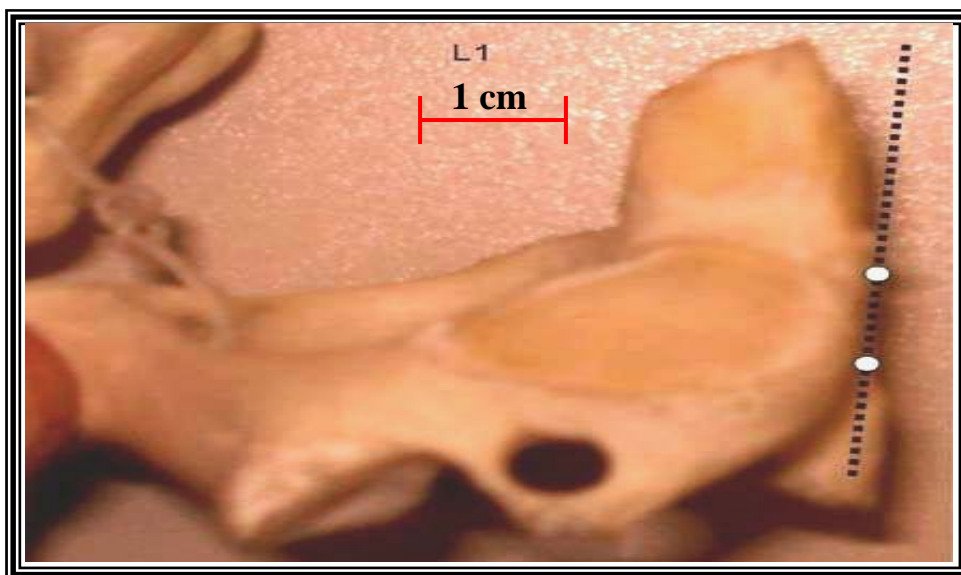
Although there is a non-significant relationship between the retroflexion (G1), with the length, and

anteroposterior thickness with dorsally deviated (D2) dens, there is positive correlation between these parameters i.e. the more retroflexed dens, come with increases in the length, thickness with dorsally deviated, and side to side parameters of the odontoid process.

There is a non-significant relationship with negative correlation between antero posterior thickness of the dens (D1), the dorsally deviated dens (G2), and side to side distance i.e. the thicker and wider dens is less dorsally deviated.

When the length of the dens increases, it may be bulges upward into the foramen magnum and compresses the brainstem and may be of a value in case of basilar invagination and brain stem compression<sup>(4)</sup>.

The study may elaborate the possibility of using the length and width of dens demonstrated in anteroposterior X-ray as a marker for the retroflexion of dens in cases of Chiari I figure 6. Thus, a preliminary diagnosis could be reached, In addition to that evaluation of anterior dens provide essential anatomic data for safer surgical procedures<sup>(15)</sup>.



**Figure1: the line which connect the upper and lower point of the anterior surface of the body of the axis (L1).**

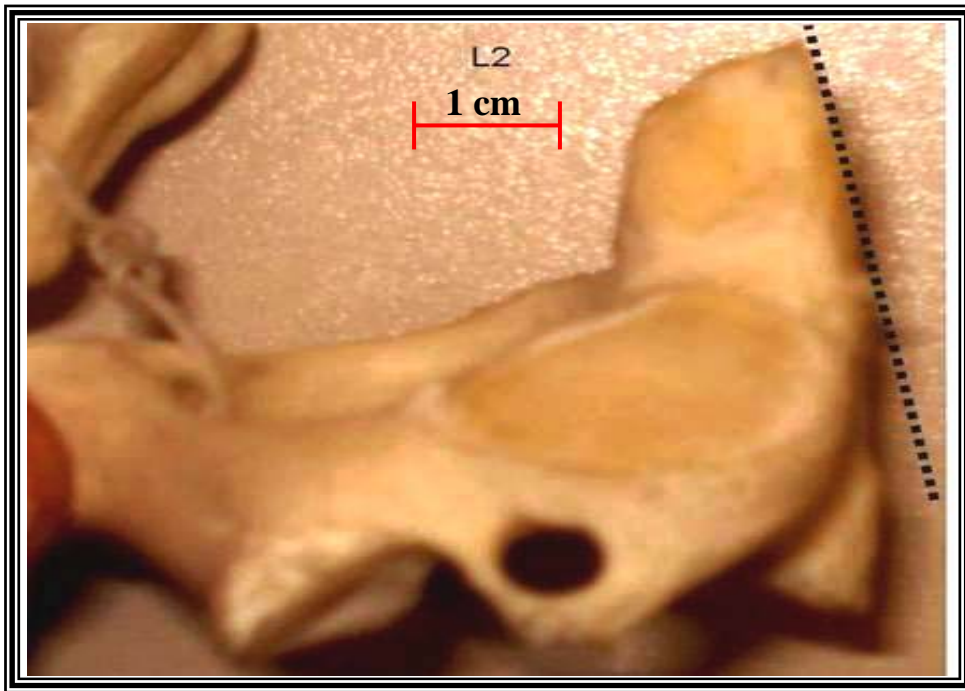


Figure2: the mid-line anterior surface of the dens is L2.

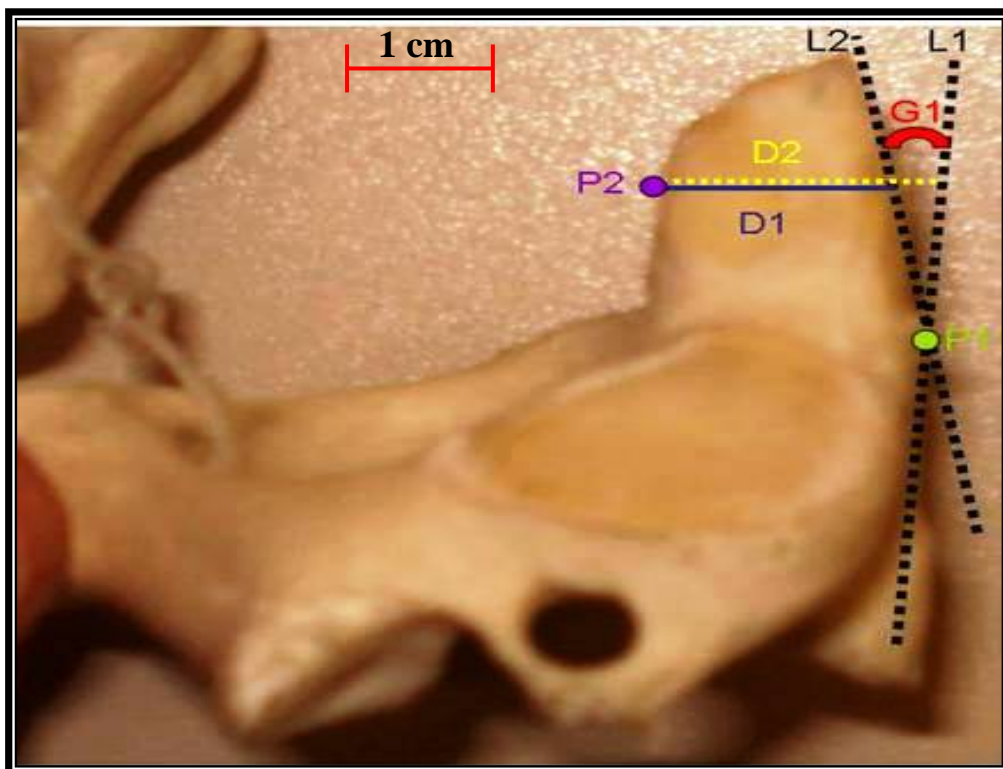


Figure 3: The angle between L1&L2 represented by (G1). P2 represents the posterior point of the posterior surface of dens, D1 represents the distance between the anterior and posterior point of dens P2, and D2 represent the distance between L1&P2.



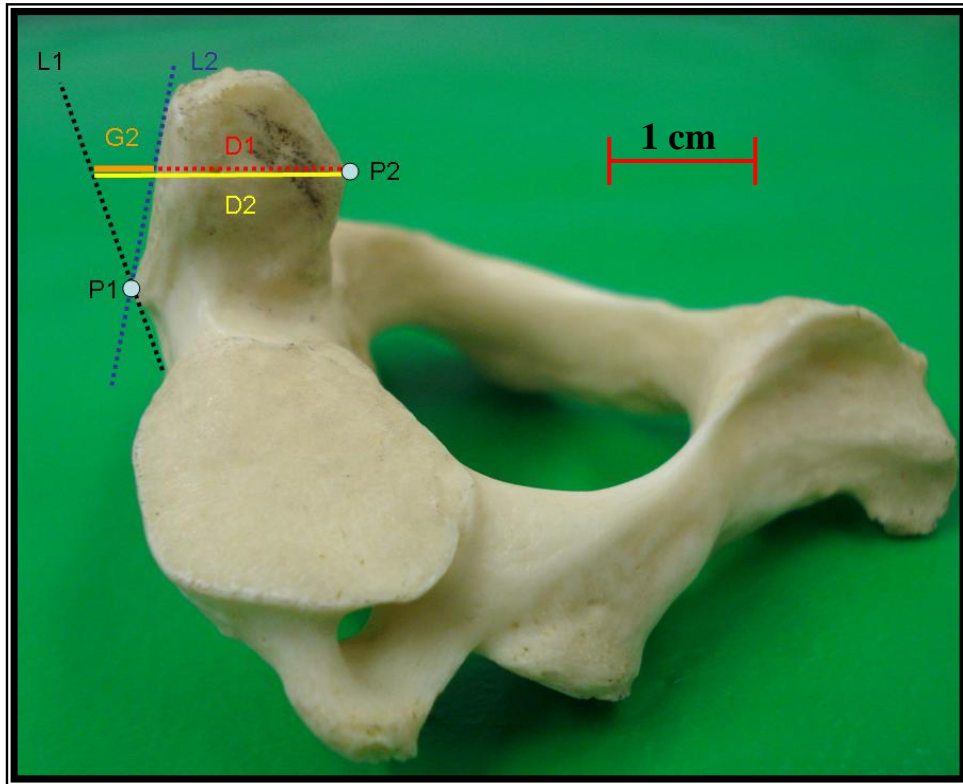


Figure 4: the deduct value between (D2-D1) represented by G2.

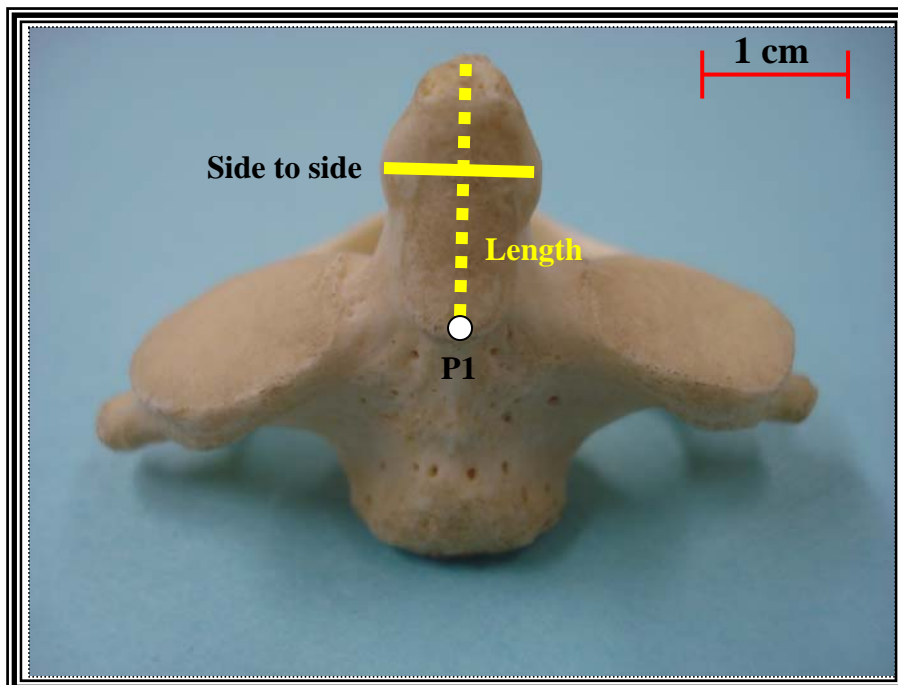
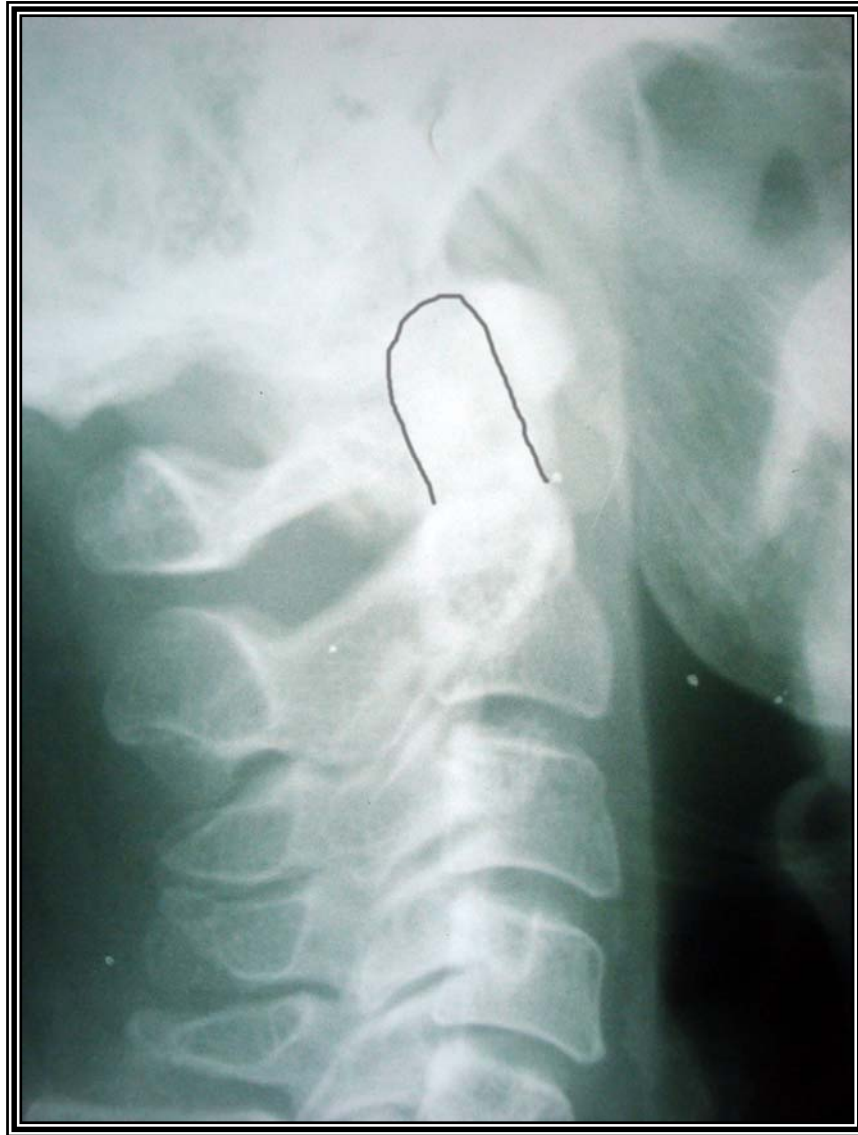

Figure5: the length and the anterior width of the dens (Side to side).



**Figure 6: odontoid process in plain X-ray (lateral view).**

**References**

1. Moore Keith L, Dalley Arthur F. Clinically Oriented Anatomy, 5th Edition Williams & Wilkins, 2006; 486.
2. Susan standing. Grays anatomy the anatomical basis in clinical practice, 39<sup>th</sup> edition Churchill livingstone, 2008; 745.
3. Hensinger RN, Fielding JW, Hawkins RJ. Congenital anomalies of the odontoid process Orthop Clin North Am. 1978; Oct; 9(4):901-12
4. Kyoshima K, Kakizawa Y, Tokushige K, Akaishi K, Kanaji M, Kuroyanagi T , Odontoid compression of the brainstem without basilar impression-- "odontoid invagination". J Clin Neurosci. 2005; Jun; 12(5):565-9
5. Menezes AH. Craniocervical developmental anatomy and its implications Childs Nerv Syst. 2008; Apr: 10.
6. Hwang SW, Heilman CB, Riesenburger RI, Kryzanski J. arthrodesis after transoral odontoidectomy and suboccipital craniectomy for ventral brain stem compression in Chiari I patients. Eur Spine, 2008; J. Jul 16.
7. Maria SS, Vidal BC and Mello MLS .Image analysis of DNA fragmentation and loss in V79 cells under apoptosis. Genetic and Molecular Biology. 2000; 23:109-112.
8. Koebke J. Morphological and functional studies on the odontoid process of the human axis Anat Embryol (Berl). 1979; Jan 30; 155(2):197-208.
9. Stevens JM, Chong WK, Barber C, Kendall BE, Crockard HA. A new appraisal of abnormalities of the odontoid process associated with atlanto-axial subluxation and neurological disability. Brain Feb; 1994 ; 117 ( Pt 1):133-48



10. Zadvornov IuN. Variants and developmental anomalies of the odontoid process of the axis Zh Vopr Neurokhir Im N N Burdenko, 1979 ;(1):30-8
11. Garant M, Oudjhane K, Sinsky A, O'Gorman AM. Duplicated odontoid process: plain radiographic and CT appearance of a rare congenital anomaly of the cervical spine. AJNR Am J Neuroradiol. 1997;Oct;18(9):1719-20
12. Milhorat Thomas H, Chou Mike W, Trinidad Elizabeth M M D, Kula Roger W M D, Mandell, Menachem MD, Wolpert, Chantelle MBA, et al. Chiari I Malformation Redefined: Clinical and Radiographic Findings for 364 Symptomatic Patients Neurosurgery. 1999; Volume 44 - Issue 5 - 1005-1017
13. Kremer P, Despaux J, Benmansour A, Wendling D. Spontaneous fracture of the odontoid process in a patient with ankylosing spondylitis. Nonunion responsible for compression of the upper cervical cord. Rev Rhum Engl Ed. Jun, 1995; 62(6):455-8.
14. Shane Tubbs<sup>1</sup>, Matthew Bailey, William C. Barrow, Marios Loukas, Mohammadali M. Shoja<sup>4</sup> and W. Jerry Oakes<sup>1</sup>, Morphometric analysis of the craniocervical juncture in children with Chiari I malformation and concomitant syringobulbia Neurosurgery vol.25 no.6, 2009; 689-692.
15. Tun K, Kaptanoglu E, Cemil B, Karahan ST, Esmer AF, Elhan A.: A neurosurgical view of anatomical evaluation of anterior C1-C2 for safer transoral odontoidectomy Eur Spine J. 2008 ; Jun;17(6):853-6.