

Hydatid Cyst of the Rib: A case report

Omar RH Al Dahhan *MBChB, FIBMS*

Dept. Cardiothoracic and Vascular Surgery, Fallujah General Hospital.

Abstract

The hydatid cyst is endemic in our country, but bone lesions are less common. The disease often takes the appearance of abscess or malignant lesion. We report a case of a 31-year-old woman with a hydatid cyst of the rib complicated with cutaneous fistula. The surgery allowed both diagnosis and treatment.

Keywords: hydatid cyst, rib, fistula.

Introduction

The hydatid cyst is a parasitic disease caused by *Echinococcus granulosus*, a cestode which remains endemic in some parts of the world.

This study is relevant to Iraq because of the exposure of its rural population to infection due to their proximity to the carnivores, sheep, and bovins. Liver (60%) and lungs (20% to 30%) are the most affected by the disease ⁽¹⁾. Osseous hydatidosis is uncommon (0.9% to 4%) especially the ribs. Bone lesions are always primary; secondary lesions are due to recurrence ⁽²⁾.

In this case, we present a patient with costal echinococcosis that looks like-as revealed by a cutaneous fistula-an infectious lesion. The course of the disease is usually slow and laboratory tests are often negative. Diagnosis is generally made through the combined assessment of clinical, radiologic, and histopathological test.

Case Report

A 31-year-old woman was admitted to our unit for a skin fistula on the right chest wall. She was not smoker and she had no history of substance abuse. Two years ago, she had

suffered from chest pain with swelling of the right chest wall. The swelling was drained two times by general surgeon in private clinic, but still there is recurrence and there is no definite diagnosis.

On admission, physical examination showed a discharging sinus beneath right breast at the right 4th rib's level, with no other abnormality. Blood cell count, hydatid serology, and inflammation markers were normal.

Chest X-rays showed an osteolytic lesion on the 4th right rib (Figure 1). The lung parenchyma and mediastinum were free.

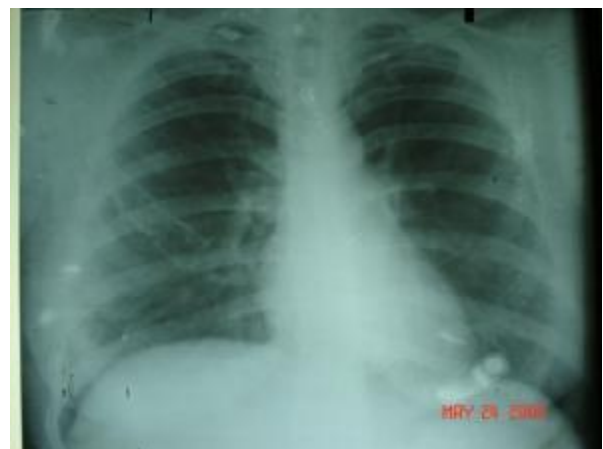

Figure 1: (PA chest x-ray) shows widening 4th rib on right side with osteolytic changes in favor of osteomyelitis.

The patient underwent a thoracotomy. An incision was performed along the lateral arch of the 4th rib, where we noticed a hydatid vesicle and bone sequesters. We resect the anterolateral arch of the 4th rib on a 12 cm length. There were no postsurgical complications. Pathological analysis revealed a hydatid cyst of the rib.

Histopathological section shows viable non complicated hydatid cyst with germinal epithelial layer, daughter cyst, laminated membrane H & E 200x (Figure 2).




Figure 2. Histopathological section shows eosinophilic laminated membrane in keeping with germinal layer of hydatid cyst. H & E 200x.

Twelve months after this surgery the patient is still in good condition and has no cyst relapse.

Discussion

Hydatidosis, caused by *Echinococcus granulosus*, is still an endemic parasitic disease in the Mediterranean area, South America, North Africa, and Australia. The most common anatomic location of hydatid disease is the liver, followed by the lung. Hydatidosis is located in the bones in 0.5% to 2% of all cases. A hydatid cyst can be seen in any part of the body⁽³⁾.

Costal hydatid disease is very rare, even in the countries where the disease is endemic. In rib lesions, hydatid cyst destroys the bone matrix and usually infiltrates adjacent tissues which, fortunately, have not happened in our specific

case⁽⁴⁾. The disease evolution is generally slow but it is important to note that complications can occur. The diagnosis is usually suspected based on the conditions of life and the radiological aspect. Serological tests might help in the diagnosis, but one has to keep in mind that the best sensitivity barely reaches 82.7% and the best specificity 94.7%⁽⁵⁾. Some authors recommend also CT scan and even ultrasound⁽⁶⁾.

Ruptured and infected hydatid cysts are often confused with tumors and/or abscesses⁽⁷⁾.

Early diagnosis is important to prevent complications. When an intrathoracic extrapulmonary hydatid cyst lies in the neighborhood of bone structures, it can cause bone destruction. Rupture of a pulmonary hydatid cyst into the pleural space, either spontaneously or during surgery, is the most common cause of pleural hydatidosis or chest wall hydatidosis⁽⁴⁾.

In this case, the hydatid cyst is primary; it involved neither the lung nor the liver. The possible mechanism of primary hydatid disease of the chest wall may be as follows: the embryo passes through the duodenal wall into either the portal vein or the periduodenal and perigastric lymphatics. Periduodenal and perigastric lymphatic channels connect with the thoracomedial lymphatic and the thoracic duct⁽⁸⁾.

The gold standard is to perform surgery in excising the entire rib and to use pre- and postoperative medical treatment⁽⁹⁾. It has been suggested that better results would be achieved by combining surgery and albendazole (10 mg/kg) for presurgery and postoperative prophylaxis, and that large doses over a long period of time would be a good clinical approach and may reduce the incidence of relapse⁽¹⁰⁾. The preference goes to surgery first followed by 6 months of postoperative prophylaxis by albendazole 400 mg/day, with monthly hepatic balance monitoring, given the risk of hepatotoxicity⁽⁹⁾.

Hydatid cyst, especially of the rib, is a very rare disease. However the reported case

demonstrates the importance of this differential diagnosis.

In conclusion, what makes this case special is the remarkably late onset of the disease. Given the patient's history, one might have been led to a wrong diagnosis, especially taking into account that radiology was inconclusive.

CT scan of the chest didn't requested as there is little clinical data that makes hydatid cyst as possible diagnosis.

So we depend on chest X-ray and histopathological report that prove a hydatid cyst and also confirm surgical findings of hydatid cyst membrane inside excised diseased rib.

References

1. Tomos P, Kakaris S, Lachanas E, and Karakatsani A. Secondary echinococcosis of the rib and soft tissues. *Respiration*, 2005; 72(5): 542.
2. Gezer S, Altinok T, Agaçkır Y, and Tastepe I. Hydatid disease of the first rib causing thoracic outlet syndrome. *Med Princip Pract*, 2007; 16(1): 68-70.
3. Ahmet H, Demir DS, Emir S, Kacar A, Tiryaki T. Primary hydatid cyst of the rib mimicking chest wall tumor: a case report. *J Pediat Surg*, 2010; 45(11): 2247-2249.
4. Lanoglu NK, Gorguner M, and Eroglu A. Hydatid disease of rib. *Ann Thora Surg*, 2001; 71(1): 372-373.
5. Stoss S, Kalbermatten DF, Robertson A, et al. Large cystic tumour at the chest wall mimicking an echinococcosis: a case report. *J Plas Reconst Aesthetic Surg*, 2008; 61(10): e13-e16.
6. Ousehal A, Adil A, El-Azhari A, and Kadiri R. Spinal cord compression disclosing rib hydatidosis. *J de Radiologie*, 1995; 76(12): 1093-1095.
7. Kilic D, Tercan F, Sahin E, Bilen A, and Hatipoglu A. Unusual radiologic manifestations of the echinococcus infection in the thorax. *J Thora Imag*, 2006; 21(1): 32-36.
8. Findikcioglu A, Kilic D, and Hatipoglu A. Primary hydatid disease of the chest wall. *Ann Thora Cardiovasc Surg*, 2007; 13(3): 203-205.
9. Stamatis G, Greschuchna D. Echinococcus cysticus costalis: report of 2 cases and review of the literature. *Pneumologie*, 1989; 43(4): 213-216.
10. Di Gesu G, Massaro M, Picone A, La Bianca A, and Fiasconaro G. Bone echinococcosis. *Minerva Medica*, 1987; 78(13): 921-931.